



**FACULTAD DE CIENCIAS DE LA SALUD**  
**CARRERA PROFESIONAL DE ESTOMATOLOGÍA**

**“CIRUGÍA DE REPOSICIONAMIENTO LABIAL: UNA REVISIÓN  
DE LA EVOLUCIÓN DE LA TÉCNICA”**

Tesis para optar el Título de:  
SEGUNDA ESPECIALIDAD EN PERIODONCIA E IMPLANTES

Presentado por:  
Kelly Consuelo Gonzales Medina (0000-0003-3801-972X)

Asesor:  
Andrea Victoria Vergara Buenaventura (0000-0002-9395-1010)

Lima- Perú

2021





**FACULTAD DE CIENCIAS DE LA SALUD**  
**CARRERA PROFESIONAL DE ESTOMATOLOGÍA**

**“CIRUGÍA DE REPOSICIONAMIENTO LABIAL: UNA REVISIÓN  
DE LA EVOLUCIÓN DE LA TÉCNICA”**

Tesis para optar el Título de:  
SEGUNDA ESPECIALIDAD EN PERIODONCIA E IMPLANTES

Presentado por:  
Kelly Consuelo Gonzales Medina (0000-0003-3801-972X)

Asesor:  
Andrea Victoria Vergara Buenaventura (0000-0002-9395-1010)

Lima- Perú

2021

## Copia del acta de sustentación



### ACTA DE SUSTENTACIÓN DE TESIS

Lima, 20 de setiembre de 2021.

Los integrantes del Jurado de tesis:

Presidente: Mg. Erick Gianmarco Valdivia Frías	<input type="checkbox"/>
Miembro: Mg. Pedro Luis Tinedo Lopez	
Miembro: Mg. Carmen Teresa Castro Ruiz	

Se reúnen para evaluar la tesis titulada: **“Cirugía de reposicionamiento labial: una revisión de la evolución de la técnica”**

Presentada por el estudiante/bachiller:

- C.D Kelly Consuelo Gonzales Medina

Para optar el Grado Académico de Especialista en Periodoncia e Implantes

Asesorada por: Mg. Andrea Victoria Vergara Buenaventura

Luego de haber evaluado el informe final de tesis y evaluado el desempeño del estudiante de la Carrera de Estomatología en la sustentación, se concluyen de:

Manera unánime ( X )

Por mayoría ( )

Calificar a:

Tesis: Kelly Gonzales Medina			Nota (en letras): Veinte
Aprobado ( )	Aprobado - Muy buena ( )	Aprobado - Sobresaliente ( X )	Desaprobado ( )

Los miembros del jurado firman en señal de conformidad.



**Mg. Erick Gianmarco Valdivia Frías**  
Presidente del Jurado  
DNI. 40137425



**Mg. Carmen Teresa Castro Ruiz**  
Miembro 2  
DNI. 10803209



**Mg. Pedro Luis Tinedo Lopez**  
Miembro 1  
DNI. 45159119



**Mg. Andrea Victoria Vergara Buenaventura**  
Asesora  
DNI. 42954579

T // (51) 610 6738  
informes@cientifica.edu.pe  
cientifica.edu.pe

### **Agradecimiento**

Agradezco a mis padres por brindarme el soporte y comprensión durante toda mi etapa académica, a mi asesora por guiarme en todo este camino compartiendo sus conocimientos; y a todos mis docentes de especialidad que siempre estuvieron dispuestos a brindarme la ayuda necesaria y más.

## I. Resumen

La técnica de reposicionamiento de labios (LRT) se considera un tratamiento seguro y predecible de sonrisa gingival (GS). Sin embargo, desde que Rubinstein y Kostianovsky lo introdujeron en 1973, ha sufrido varias modificaciones. Este artículo tiene como objetivo revisar y proporcionar una recopilación histórica de la evolución de la técnica de reposicionamiento de labios (LRT) para ayudar a los médicos a comprender la descripción de cada técnica y la justificación de sus modificaciones para tratar el GS.

Se realizó una búsqueda electrónica en Medline, Scopus y Cochrane Library hasta diciembre de 2020, que incluyó los términos "reposicionamiento de labios", "técnica de reposicionamiento de labios" o "cirugía de reposicionamiento de labios" y estudios que evalúan o discuten en detalle la modificación del LRT original. La búsqueda no tiene restricciones de idioma ni de tiempo. Además, se realizó una búsqueda manual de las referencias de todos los artículos incluidos.

Las modificaciones descritas en la literatura incluyen rotura muscular, disección subperióstica de la encía, frenectomías y el uso de productos adyuvantes. Su objetivo es minimizar las recaídas, la morbilidad y mejorar la estabilidad. El malestar, la formación de cicatrices y el dolor fueron las complicaciones más frecuentes reportadas. La elección de utilizar una modificación debe analizarse y personalizarse de acuerdo con las necesidades individuales del paciente

## II. Abstract

The lip repositioning technique (LRT) is considered a safe and predictable gummy smile (GS) treatment. However, since Rubinstein and Kostianovsky introduced it in 1973, it has undergone several modifications. This article aims to review and provide a historical compilation of the lip repositioning technique (LRT) evolution to help clinicians understand each technique's description and the rationale for its modifications to treat GS.

An electronic search was performed in Medline, Scopus, and Cochrane Library up to December 2020, including the terms "lip repositioning," "lip repositioning technique," or "lip repositioning surgery" and studies evaluating or discussing the original LRT's modification in detail. The search has no language or time restrictions. Additionally, a hand-searching of the references of all included articles was performed.

Modifications described in the literature include muscle severance, subperiosteal dissection of the gingiva, frenectomies, and the use of adjuvant products. They aim to minimize relapse, morbidity and improve stability. Discomfort, scar formation, and pain were the most frequent complications reported. The choice to use a modification should be analyzed and customized to the individual patient's needs.

Keywords: Excessive Gingival Display; Gummy Smile; Lip Repositioning technique; smile

### III. Versión aprobada para publicar (la estructura dependerá de la revista elegida)

Type of article: Review Article

Title of the article: **The Lip Repositioning Surgery: A Review of the Technique's Evolution**

Running title : The Lip Repositioning Technique: A Review

Contributors

1. Gonzales-Medina, Kelly, DDS, Department of Periodontology, School of Dentistry, Universidad Científica del Sur, Lima, Peru..
2. Mendoza-Geng, Andrea, DDS, Department of Periodontology, School of Dentistry, Universidad Científica del Sur, Lima, Peru.
3. Vergara-Buenaventura, Andrea, DDS, MSc, PhD(s), Department of Periodontology, School of Dentistry, Universidad Científica del Sur, Lima, Peru.

Department(s) and institution(s)

Department of Periodontology, School of Dentistry, Universidad Científica del Sur, Lima, Peru.

Corresponding Author:

Dr. Andrea Vergara Buenaventura. Universidad Científica del Sur, Calle Cantuarias 398, 15048, Miraflores, Lima, Perú.

Tel. +51994968218

Email: [avergarab@cientifica.edu.pe](mailto:avergarab@cientifica.edu.pe)

<https://orcid.org/0000-0002-9395-1010>



Total number of pages: 7

Total number of photographs: 3

Word counts

for abstract: 177

for the text: 3533

Source(s) of support: no

Conflicting Interest (If present, give more details): The authors do not have any financial interest in the companies whose materials are included in this article

## The Lip Repositioning Surgery: A Review of the Technique's Evolution

### Abstract

The lip repositioning technique (LRT) is considered a safe and predictable gummy smile (GS) treatment. However, since Rubinstein and Kostianovsky introduced it in 1973, it has undergone several modifications. This article aims to review and provide a historical compilation of the lip repositioning technique (LRT) evolution to help clinicians understand each technique's description and the rationale for its modifications to treat GS.

An electronic search was performed in Medline, Scopus, and Cochrane Library up to December 2020, including the terms "lip repositioning," "lip repositioning technique," or "lip repositioning surgery" and studies evaluating or discussing the original LRT's modification in detail. The search has no language or time restrictions. Additionally, a hand-searching of the references of all included articles was performed.

Modifications described in the literature include muscle severance, subperiosteal dissection of the gingiva, frenectomies, and the use of adjuvant products. They aim to minimize relapse, morbidity and improve stability. Discomfort, scar formation, and pain were the most frequent complications reported. The choice to use a modification should be analyzed and customized to the individual patient's needs.

Keywords: Excessive Gingival Display; Gummy Smile; Lip Repositioning technique; smile

## Introduction

According to some authors, the "ideal smile" involves 1 to 3 mm of exposed gingiva.<sup>[1-3]</sup> Thus, the excessive gingival display (EGD), also called gummy smile (GS), is an aesthetic problem that may affect a person's appearance.<sup>[4-7]</sup> This condition is more frequent in women and during smiling<sup>[8, 9]</sup> and has a prevalence between 11.8%<sup>[10]</sup> and 10.57%.<sup>[11]</sup>

Typically, a patient is diagnosed with GS or EGD when having a high smile line, showing more than 2 mm of free gingiva.<sup>[12]</sup> A thorough examination and correct diagnosis are essential to achieve aesthetic and predictable treatment results.<sup>[13]</sup> It is necessary to emphasize that before any surgical treatment, the gummy smile's etiology must be identified. The GS's etiology is often multifactorial, including altered passive eruption (APE), vertical maxillary excess (VME), anterior dentoalveolar extrusion, gingival enlargement, hypermobile upper lip (HUL), short lip, and asymmetrical upper lip.<sup>[2, 9, 14, 15]</sup> When a patient presents gross overbite, VME or overgrowth of the upper jaw, orthognathic surgery is the first recommended option.<sup>[4]</sup> However, most patients refuse this surgery due to its high morbidity and the need to be hospitalized.<sup>[16, 17]</sup>

The lip repositioning technique (LRT) described for the first time in plastic surgery by Rubinstein and Kostianovsky<sup>[18]</sup>, is a widely used, effective, safe, and predictable treatment with an average GS reduction of 2.71 mm.<sup>[19, 20]</sup> The LRT alone could be used when the patient presents short upper lip, HUL (lip mobility >8 mm), and VME except for severe cases<sup>[14, 19, 21]</sup>. However, the literature describes several modifications of the original LRT using myotomies, subperiosteal dissection of the gingiva, and adjunctive product use.<sup>[22-24]</sup>

Therefore, this article aims to review and provide a historical compilation of the lip repositioning technique (LRT) evolution to help clinicians understand each technique's description and the rationale for its modifications to treat GS.

## **Material and methods**

### Search strategy

An electronic search in Medline (via Pubmed), Scopus, and Cochrane Library (CENTRAL) was performed up to December 2020 to conduct a comprehensive review of the literature and answer the following questions:

1. What are the different modifications of the original LRT?
2. Which are the basis of the different modifications of the LRT?
3. Which are the main complications of the LRT modifications?

The search strategy included the terms "lip repositioning," "lip repositioning technique," or "lip repositioning surgery" to identify the relevant studies. The search has no language or time restrictions. Additionally, a hand-searching of the references of all included articles was performed.

### Inclusion/exclusion criteria

Randomized or non-randomized clinical trials, case series, and case reports were considered for inclusion if they described a modification of the original LRT<sup>[18]</sup>. Articles that did not provide suitable detail or description of the technique used were excluded.

### The Original lip repositioning technique

Rubinstein and Kostianovsky first presented the LRT in 1972 and published it in the plastic surgery field one year later.<sup>[18, 25]</sup> The surgery was based on a strip of maxillary labial mucosa excision to eliminate the lip "over-excursion" while smiling. The gingival display is measured from the gingival margin to the lower border of the upper lip during smiling (Figure 1). This technique performed a turndown flap to close the wound with the lower edge. The distal references of the horizontal incision coincide with the labial commissures' projection during the smile, at the second maxillary molars level. The upper edge of the horizontal incision was placed at the bottom of the upper buccal sulcus, and the lower edge 2 -3 mm above the dentoalveolar line sectioning the frenum. The removal of mucosa was partial, leaving the periosteum intact (Figure 2). Finally, the lip was immobilized using plaster or adhesive tape.

### Study Selection and Data extraction

Two independent researchers (KG and A.M.) independently performed the search strategy. Titles and abstracts were independently assessed to identify relevant clinical studies. Full-text articles screening was performed to identify articles that met the inclusion criteria. Then, the same reviewers extracted data from the selected articles into tables. Any disagreement was resolved by consensus with a third examiner (A.V.)

Included articles were thoroughly assessed for content related to the LRT surgical modification technique. The extracted data included: Author (year), modifications on the lower and upper horizontal incision, distal extension references, flap/incision type, information about frenulum section, muscular modifications, use of Adjuvants. Also, data were summarized on all postoperative complications.

## Results

A total of 633 citations were screened from three databases; 335 from Scopus, 241 from Medline via Pubmed, and 57 from Cochrane. Figure 3 shows the flowchart diagram. After the removal of duplicated articles, 420 articles remained for title and abstract screening. And after full-text assessment, only 23 studies remained for data extraction. The main modifications related to muscle severance or detachment, frenectomies, the horizontal incision extension, and complications reported are shown in Table 1

The lower horizontal incision along the mucogingival junction was the technique of choice. However, concerning the upper horizontal incision, authors report performing it on the sulcus<sup>[5]</sup>, the labial mucosa<sup>[4, 26]</sup>. In contrast, others perform an apical projection to the inferior incision at 5mm<sup>[27]</sup>, 6 to 8mm<sup>[28]</sup>, 8mm<sup>[29]</sup>, 8 to 10mm<sup>[29, 30]</sup>, between 10 and 12 mm<sup>[23, 24]</sup> or twice the amount of the EGD<sup>[31-35]</sup>. The most frequent reference for the distal projection of the horizontal incision was the maxillary first molar.<sup>[21, 23, 30, 32, 35, 36]</sup>. 6 authors performed a full-thickness incision<sup>[4, 5, 21, 26, 29, 37]</sup> and 13 reported sectioning the labial frenulum.

Concerning muscle severance (Figure 4), the authors recommended muscle detached in cases of short lips<sup>[4]</sup>, muscle amputation<sup>[5, 21, 24, 33, 37]</sup>, and muscle containment with sutures<sup>[30]</sup>. On the other hand, some authors recommend combining LRT with other therapeutic options to ensure more predictable and stable results. The most common adjuvant used were botulinum toxin (BT),<sup>[28, 35]</sup> and spacers<sup>[38, 39]</sup>. LRT with gingivectomy and osteotomy<sup>[26, 40-43]</sup> was the most frequent associated surgery. Table 2 shows the summary of the adjuvants used in combination with the LRT.

Across all studies, the most frequent postoperative complication was discomfort, scar formation<sup>[21, 23, 28, 29, 31, 32, 36]</sup>, and pain<sup>[18, 21, 29, 36]</sup>. Other LRT modifications reported

swelling,<sup>[28, 33]</sup> ecchymosis,<sup>[36]</sup> edema of the upper lip and perioral area,<sup>[21, 29]</sup> minor bleeding<sup>[21, 29]</sup>, and mucocele formation.<sup>[36]</sup>

## Discussion

Among the procedures used to improve GS, the LRT reduces the elevator smile muscle's retraction by shortening the vestibule, reducing the EGD when smiling<sup>[44]</sup>. It was first presented in 1972, published in the plastic surgery field by Rubinstein and Kostianovsky<sup>[18, 25]</sup>, and introduced years later in the dental cosmetic area by Rosenblat and Simon<sup>[36]</sup>. This procedure has been suggested for patients requesting a less invasive procedure compared with orthognathic surgery<sup>[16, 17]</sup> and has evolved significantly over the years.

Litton and Fournier<sup>[4]</sup> were the first to review it in 1979, recommending a horizontal incision using the first bicuspid medial side as a reference and a full-thickness flap. Also, suggested muscle detached in cases of short lips. Miskinyar<sup>[5]</sup> performed the original technique, finding relapses in his patients, and modified it by performing an amputation of the levator labii superioris muscle (LLSM). After reporting that muscle severance improved EGD reduction, different authors started to perform the technique using a full-thickness flap and the levator muscle myotomy.<sup>[21, 24, 33]</sup> They indicated that this method alters the smile muscles' position, avoiding muscle pull.

Ishida et al.<sup>[37]</sup> proposed a technique to reduce the elevator of the upper lip muscle function and a frenectomy to lengthen the upper lip. However, it required a subperiosteal dissection through the columella and lateral incisions inside the nostrils. Abdullah et al.<sup>[29]</sup> performed a full-thickness incision 4 to 5 mm above the gingival margins from the second premolar level to the contralateral and a parallel line using a surgical caliper at approximately 8 to 10 mm apical to the first incision. After removing the soft tissue strip, the LLSM and depressor septi muscles were released and repositioned in a lower position

using circumferential sutures around the canines. Authors who support this modification using myotomy of the LLM reported fewer recurrences and greater postoperative stability than the conventional technique<sup>[24]</sup>. Although myotomy showed a trend of greater reduction in EGD at 6-month follow-up, there are no longer-term data<sup>[20]</sup>.

the most frequent postoperative complication was discomfort, scar formation<sup>[21, 23, 28, 29, 31, 32, 36]</sup>, and pain<sup>[18, 21, 29, 36]</sup>. Other LRT modifications reported swelling,<sup>[28, 33]</sup> ecchymosis,<sup>[36]</sup> edema of the upper lip and perioral area,<sup>[21, 29]</sup> minor bleeding<sup>[21, 29]</sup>, and mucocele formation.<sup>[36]</sup>

Rosenblat and Simon<sup>[36]</sup> performed the horizontal incision over the mucogingival line from the first molar sectioning the frenulum. They also recommended that the amount of tissue removed should be twice the amount of gingival tissue exposed with a maximum of 10-12 mm. Jacob and Jacob<sup>[31]</sup> evaluated the LRT with a reversible trial before mucosal cutting using sutures. Then, the incisions and the frenectomy were performed using a high-power diode laser (975 nm, 4 W, CW).

On the other hand, some modifications included leaving the maxillary labial frenulum intact. Ribeiro – Junior et al.<sup>[23]</sup> modified the surgical procedure described by Rosenblat and Simon<sup>[36]</sup> involving two mucosal strip removal, leaving exposed the connective tissue from the midline to the first upper molar and maintaining the frenulum intact. In the same way, Torabi et al.<sup>[32]</sup> avoided cutting the frenulum and performed periosteal fenestrations. They used extraoral tapes to stabilize tissues as the original LRT.<sup>[25]</sup> Similarly, Bhola et al.<sup>[14]</sup> published a new GS classification and introduced the lip stabilization technique (LipStaT), avoiding sectioning the frenulum.

Recent modifications aimed to change the mucogingival junction position to a more coronal one without removing a mucosal strip<sup>[27]</sup>. Alternatively, some authors perform a



customized calculation based on the amount of gingiva shown for each tooth area<sup>[34]</sup> and smile and papillary exposure.<sup>[26]</sup>

Combining the LRT with other approaches such as periodontal plastic surgeries, restorative procedures, or BT injections has been suggested to obtain more predictable and stable results <sup>[20]</sup>. A review of the use of adjuvants is shown in Table 3. Ellenbogen and Swara<sup>[38]</sup> tried to improve the LRT by partial transection of the LLSM by inserting silicone spacers and Supramid implants into a pocket created by an incision inside the nostrils. Spacers were intended to fill the muscle space to prevent future reinsertion at the same level. However, the authors reported rejection of Supramid implants. Similarly, it has been suggested to use polymethylmethacrylate (PMMA)-based bone cement fixed to the bone with fixation screws in maxillary overgrowth and subnasal skeletal depression, producing a retraction of the upper during smiling. <sup>[39]</sup>

On the other hand, some authors recommend using the LRT with other therapeutic options in cases of APE, gingival enlargement, and preventing relapse<sup>[20, 27, 45]</sup>. One approach is with gingivectomy,<sup>[23]</sup> in association with gingivectomy and osteotomy<sup>[26, 40-42]</sup> and even with digital workflows<sup>[46]</sup>.

BT type A has been recommended in cases of excessive muscle function and HUL to prevent muscle contraction.<sup>[47]</sup> Aly et al. suggested using it as an adjuvant two weeks after the lip repositioning surgery<sup>[28]</sup> and other authors the day after. <sup>[35]</sup> BT injections produce lip immobilization during the healing phase, providing long-term stability of the LRT. <sup>[28,</sup>

35]

## **Conclusion**

Many LRT modifications have been described in the literature and aim to improve the original technique somehow. To optimize technique selection, an individualized approach is necessary. Several authors support the use of muscle severance to prevent the smile muscle from returning to its original position. In contrast, others use adjuvant products to prevent muscle movement during the healing process and minimize potential morbidity. The frenulum section's choice and the extension of the horizontal incision should be customized to the individual patient's needs. The combination with other approaches may ensure more predictable and stable results. Finally, clinicians should know the techniques, advantages, and possible complications to ensure better outcomes.

## REFERENCES

- [1] Springer NC, Chang C, Fields HW, Beck FM, Firestone AR, Rosenstiel S, et al. Smile esthetics from the layperson's perspective. 2011;139:e91-e101.
- [2] Garber DA, Salama MA. The aesthetic smile: diagnosis and treatment. *Periodontology* 2000. 1996;11:18-28. doi: 10.1111/j.1600-0757.1996.tb00179.x.
- [3] Kokich VO, Jr., Kiyak HA, Shapiro PA. Comparing the perception of dentists and lay people to altered dental esthetics. *Journal of esthetic dentistry*. 1999;11:311-24. doi: 10.1111/j.1708-8240.1999.tb00414.x.
- [4] Litton C, Fournier P. Simple surgical correction of the gummy smile. *Plastic and reconstructive surgery*. 1979;63:372-3. doi: 10.1097/00006534-197903000-00014.
- [5] Miskinyar SA. A new method for correcting a gummy smile. *Plastic and reconstructive surgery*. 1983;72:397-400. doi: 10.1097/00006534-198309000-00027.
- [6] Guo J, Gong H, Tian W, Tang W, Bai D. Alteration of gingival exposure and its aesthetic effect. *J Craniofac Surg*. 2011;22:909-13. doi: 10.1097/SCS.0b013e31820f7f7a.
- [7] Ayyildiz E, Tan E, Keklik H, Demirtag Z, Celebi AA, Pithon MM. Esthetic impact of gingival plastic surgery from the dentistry students' perspective. *European journal of dentistry*. 2016;10:397-402. doi: 10.4103/1305-7456.184164.
- [8] Al-Habahbeh R, Al-Shammout R, Al-Jabrah O, Al-Omari F. The effect of gender on tooth and gingival display in the anterior region at rest and during smiling. *The European journal of esthetic dentistry : official journal of the European Academy of Esthetic Dentistry*. 2009;4:382-95.
- [9] Peck S, Peck L, Kataja M. Some vertical lineaments of lip position. *Am J Orthod Dentofacial Orthop*. 1992;101:519-24. doi: 10.1016/0889-5406(92)70126-u.
- [10] Elhiny OJEOJ. Prevalence of gummy smile in a sample of Egyptian population and laymen perception of its attractiveness. 2014;45:35-42.
- [11] Tjan AH, Miller GD, The JG. Some esthetic factors in a smile. *J Prosthet Dent*. 1984;51:24-8. doi: 10.1016/s0022-3913(84)80097-9.
- [12] Monaco A, Streni O, Marci MC, Marzo G, Gatto R, Giannoni M. Gummy smile: clinical parameters useful for diagnosis and therapeutical approach. *The Journal of clinical pediatric dentistry*. 2004;29:19-25. doi: 10.17796/jcpd.29.1.y0113r4m06q3k2x0.
- [13] Silberberg N, Goldstein M, Smidt A. Excessive gingival display--etiology, diagnosis, and treatment modalities. *Quintessence Int*. 2009;40:809-18.
- [14] Bholra M, Fairbairn PJ, Kolhatkar S, Chu SJ, Morris T, de Campos M. LipStaT: The Lip Stabilization Technique- Indications and Guidelines for Case Selection and Classification of Excessive Gingival Display. *The International journal of periodontics & restorative dentistry*. 2015;35:549-59. doi: 10.11607/prd.2059.
- [15] Andijani RI, Tatakis DN. Hypermobility upper lip is highly prevalent among patients seeking treatment for gummy smile. *Journal of periodontology*. 2019;90:256-62. doi: 10.1002/jper.18-0468.
- [16] Paik CH, Park HS, Ahn HW. Treatment of vertical maxillary excess without open bite in a skeletal Class II hyperdivergent patient. *The Angle orthodontist*. 2017;87:625-33. doi: 10.2319/101816-753.1.
- [17] Tomaz AFG, Marinho LCN, de Aquino Martins ARL, Lins R, de Vasconcelos Gurgel BC. Impact of orthognathic surgery on the treatment of gummy smile: an integrative review. *Oral and maxillofacial surgery*. 2020;24:283-8. doi: 10.1007/s10006-020-00857-4.
- [18] Kostianovsky AS, Rubinstein AM. The "Unpleasant" smile. *Aesthetic Plast Surg*. 1976;1:161-6. doi: 10.1007/bf01570248.
- [19] Dym H, Pierre R, 2nd. Diagnosis and Treatment Approaches to a "Gummy Smile". *Dental clinics of North America*. 2020;64:341-9. doi: 10.1016/j.cden.2019.12.003.

- [20] Dos Santos-Pereira SA, Cicareli Á J, Idalgo FA, Nunes AG, Kassis EN, Castanha Henriques JF, et al. Effectiveness of lip repositioning surgeries in the treatment of excessive gingival display: A systematic review and meta-analysis. *Journal of esthetic and restorative dentistry : official publication of the American Academy of Esthetic Dentistry* [et al]. 2020. doi: 10.1111/jerd.12695.
- [21] Alammar AM, Heshmeh OA. Lip repositioning with a myotomy of the elevator muscles for the management of a gummy smile. *Dent Med Probl.* 2018;55:241-6. doi: 10.17219/dmp/92317.
- [22] Silva CO, Ribeiro-Júnior NV, Campos TV, Rodrigues JG, Tatakis DN. Excessive gingival display: treatment by a modified lip repositioning technique. *Journal of clinical periodontology.* 2013;40:260-5. doi: 10.1111/jcpe.12046.
- [23] Ribeiro-Júnior NV, Campos TV, Rodrigues JG, Martins TM, Silva CO. Treatment of excessive gingival display using a modified lip repositioning technique. *Int J Periodontics Restorative Dent.* 2013;33:309-14. doi: 10.11607/prd.1325.
- [24] Alammar A, Heshmeh O, Mounajjed R, Goodson M, Hamadah O. A comparison between modified and conventional surgical techniques for surgical lip repositioning in the management of the gummy smile. *Journal of esthetic and restorative dentistry : official publication of the American Academy of Esthetic Dentistry* [et al]. 2018;30:523-31. doi: 10.1111/jerd.12433.
- [25] Rubinstein A, Kostianovsky AJPMA. Cirugia estetica de la malformacion de la sonrisa. 1973;60:952.
- [26] Chacon G. Modified lip-repositioning technique for the treatment of gummy smile. *The international journal of esthetic dentistry.* 2020;15:474-88.
- [27] Zardawi FM, Gul SS, Fatih MT, Hama BJ. Surgical Procedures Reducing Excessive Gingival Display in Gummy Smile Patients With Various Etiologic Backgrounds. *Clinical advances in periodontics.* 2020;10:130-4. doi: 10.1002/cap.10089.
- [28] Aly LA, Hammouda NI. Botox as an adjunct to lip repositioning for the management of excessive gingival display in the presence of hypermobility of upper lip and vertical maxillary excess. *Dental research journal.* 2016;13:478-83. doi: 10.4103/1735-3327.197039.
- [29] Abdullah WA, Khalil HS, Alhindi MM, Marzook H. Modifying gummy smile: a minimally invasive approach. *J Contemp Dent Pract.* 2014;15:821-6. doi: 10.5005/jp-journals-10024-1625.
- [30] Littuma GJS, de Souza HCM, Peñarrieta GM, Magini RS, Saba-Chujfi E. Lip Repositioning Technique With Smile Elevator Muscle Containment - A Novel Cosmetic Approach for Gummy Smile: Case Report. *Compend Contin Educ Dent.* 2017;38:e9-e12.
- [31] Jacobs PJ, Jacobs BP. Lip repositioning with reversible trial for the management of excessive gingival display: a case series. *The International journal of periodontics & restorative dentistry.* 2013;33:169-75. doi: 10.11607/prd.1483.
- [32] Torabi A, Najafi B, Drew HJ, Cappetta EG. Lip Repositioning with Vestibular Shallowing Technique for Treatment of Excessive Gingival Display with Various Etiologies. *The International journal of periodontics & restorative dentistry.* 2018;38:e1-e8. doi: 10.11607/prd.3120.
- [33] Tawfik OK, Naiem SN, Tawfik LK, Yussif N, Meghil MM, Cutler CW, et al. Lip repositioning with or without myotomy: A randomized clinical trial. *Journal of periodontology.* 2018;89:815-23. doi: 10.1002/jper.17-0598.
- [34] Duruel O, Erduran NE, Tözüm TF. A Modification for Treatment of Excessive Gingival Display: Tooth-Based Lip-Repositioning Technique. *Int J Periodontics Restorative Dent.* 2020;40:457-61. doi: 10.11607/prd.4465.

- [35] Vergara-Buenaventura A, Mayta-Tovalino F, Correa A, Breen E, Mendoza-Azpur G. Predictability in Lip Repositioning with Botulinum Toxin for Gummy Smile Treatment: A 3-Year Follow-up Case Series. *The International journal of periodontics & restorative dentistry*. 2020;40:703-9. doi: 10.11607/prd.4645.
- [36] Rosenblatt A, Simon Z. Lip repositioning for reduction of excessive gingival display: a clinical report. *The International journal of periodontics & restorative dentistry*. 2006;26:433-7.
- [37] Ishida LH, Ishida LC, Ishida J, Grynglas J, Alonso N, Ferreira MC. Myotomy of the levator labii superioris muscle and lip repositioning: a combined approach for the correction of gummy smile. *Plast Reconstr Surg*. 2010;126:1014-9. doi: 10.1097/PRS.0b013e3181e3b6d4.
- [38] Ellenbogen R, Swara N. The improvement of the gummy smile using the implant spacer technique. *Annals of plastic surgery*. 1984;12:16-24. doi: 10.1097/00000637-198401000-00004.
- [39] Arcuri T, da Costa MFP, Ribeiro IM, Barreto BDJ, Lyra eSilva JP. Labial repositioning using polymethylmethacrylate (PMMA)-based cement for esthetic smile rehabilitation-A case report. *International journal of surgery case reports*. 2018;49:194-204. doi: 10.1016/j.ijscr.2018.07.008.
- [40] Mantovani MB, Souza EC, Marson FC, Corrêa GO, Progiante PS, Silva CO. Use of modified lip repositioning technique associated with esthetic crown lengthening for treatment of excessive gingival display: A case report of multiple etiologies. *Journal of Indian Society of Periodontology*. 2016;20:82-7. doi: 10.4103/0972-124x.164746.
- [41] Sánchez IM, Gaud-Quintana S, Stern JK. Modified Lip Repositioning with Esthetic Crown Lengthening: A Combined Approach to Treating Excessive Gingival Display. *The International journal of periodontics & restorative dentistry*. 2017;37:e130-e4. doi: 10.11607/prd.3124.
- [42] Bhimani RA, Sofia ND. Lip Repositioning, Aesthetic Crown Lengthening, and Gingival Depigmentation: A Combined Approach for a Gummy Smile Makeover. *Journal of cutaneous and aesthetic surgery*. 2019;12:240-3. doi: 10.4103/jcas.Jcas\_25\_19.
- [43] Boeira PO, De Rossi A, Caporossi LS, Lima GDS. Periodontal esthetic surgery to improve a natural smile: Report case with 2-year follow-up. *Journal of Indian Society of Periodontology*. 2020;24:87-91. doi: 10.4103/jisp.jisp\_477\_18.
- [44] Simon Z, Rosenblatt A, Dorfman WJTjocd. Eliminating a gummy smile with surgical lip repositioning. 2007;23.
- [45] Gibson MP, Tatakis DN. Treatment of Gummy Smile of Multifactorial Etiology: A Case Report. *Clinical advances in periodontics*. 2017;7:167-73. doi: 10.1902/cap.2017.160074.
- [46] Ahmed WM, Hans A, Verhaeghe TV, Nguyen C. Managing Excessive Gingival Display Using a Digital Workflow. *Journal of prosthodontics : official journal of the American College of Prosthodontists*. 2020;29:443-7. doi: 10.1111/jopr.13181.
- [47] Polo M. Botulinum toxin type A in the treatment of excessive gingival display. *Am J Orthod Dentofacial Orthop*. 2005;127:214-8; quiz 61. doi: 10.1016/j.ajodo.2004.09.013.

**Figure Legends**

Figure 1. Illustration of the preoperative gummy smile evaluation.

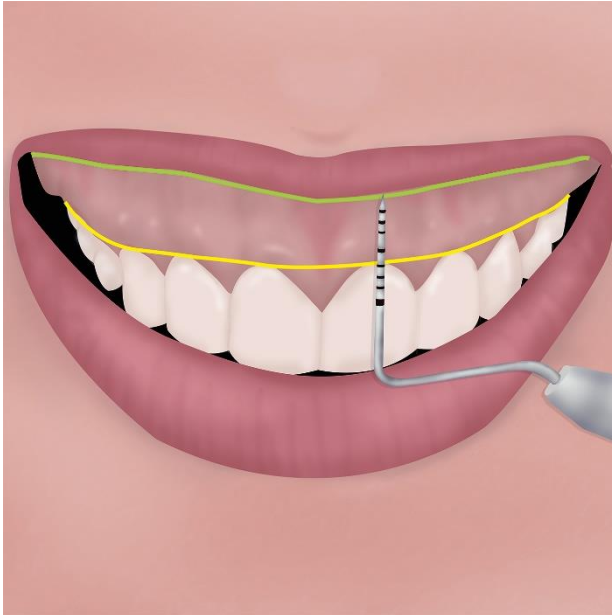


Figure 2. Illustration showing the surgical removal of the mucosal strips.

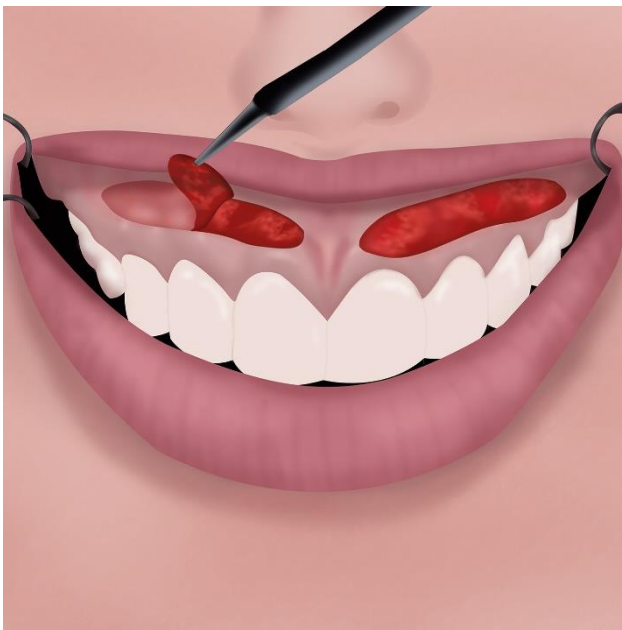




Figure 3 Flowchart diagram of the study selection

Fig 3. Prisma Flow chart

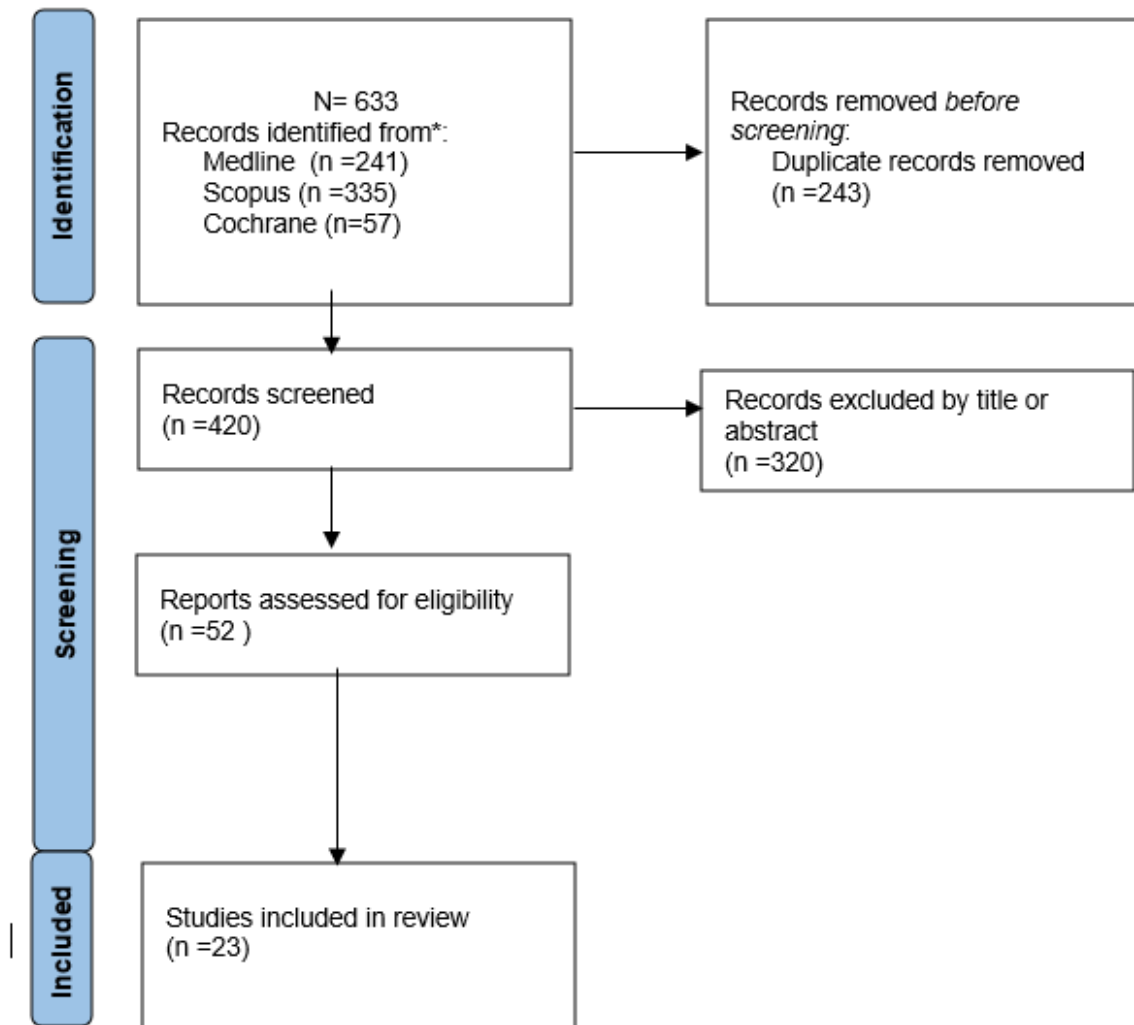
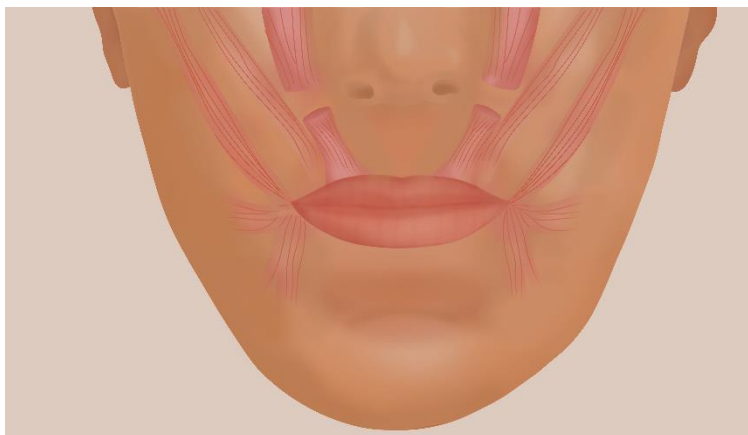


Figure 4. Illustration of the smile muscles showing amputation of both levator labii superioris muscles. Adapted from Ishida et al.<sup>[37]</sup>



<b>Author, (year)</b>	<b>Lower horizontal Incision</b>	<b>Upper horizontal Incision</b>	<b>Distal extension reference</b>	<b>Flap/incision type</b>	<b>Frenulum Section</b>	<b>Muscular modifications</b>	<b>Use of Adjuvants</b>	<b>Complications reported</b>
Rubinstein and Kostianovsky (1973) <sup>[1]</sup>	2 to 3 mm above the dentoalveolar line	At the vestibular sulcus fundus	Projection of the labial commissure s. Second upper molar	Partial-thickness	Yes	N/R	N/R	Mild pain, recurrence
Litton and Fournier, (1979) <sup>[2]</sup> .	In gum, 3-4mm above upper anterior teeth	Along the inner lip mucosa	Medial side of first bicuspid	Full thickness flap	Yes	Muscle detached in cases of short lip	N/R	N/R
Miskinyar, (1983) <sup>[3]</sup>	N/R	Into the sulcus and transversely perpendicular to the bone	N/R	Full thickness flap	N/R	Total or partial Amputation of the levator labii superioris muscle (LLSM).	N/R	Paresthesia
Ellenbogen and Swara, (1984) <sup>[4]</sup>	N/R	From columella to the nostril base	nostril base	Supraperiostically	N/R	the levator labii superioris muscle is partially transected	Silicon, cartilage, turbinate bone and supramid spacers	Supramid implant rejection Relapse, funny look complaint.



Rosenblat and Simon, (2006) <sup>[5]</sup>	At the mucogingival junction	10 to 12 mm parallel to the first one, in the labial mucosa	Maxillary first molar	Partial-thickness incision	yes	N/R	N/R	Minimal ecchymosis and tension, slight pain, scar and mucocele formation
Ishida et al., (2010) <sup>[6]</sup>	N/R	5-mm incision in the columella between the caudal septum and alar cartilages	Labial commissures	Full thickness	Yes	Muscular dissection	N/R	uneventful
Ribeiro – Junior et al. (2013) <sup>[7]</sup>	1 mm coronal to the mucogingival margin	10 to 12 mm apical and parallel to the first one	Maxillary first molar	Partial-thickness incision	No	No	N/R	Minimal discomfort, minor scar
Jacobs and Jacobs (2013) <sup>[8]</sup>	At the mucogingival junction	At a distance based on twice the desired repositioning with a moustache shape, slightly inferior the frenum.	Maxillary first molar	No mucosa removal at the trial, then performed a partial-thickness incision.	Yes	No	Suture placing for reversible trial lip repositioning	Mild discomfort

Abdullah et al. (2014) <sup>[9]</sup>	4 to 5 mm above the gingival margins	Parallel and 8 to 10 mm apical to the first incision	Second Premolar	Full thickness incision	Yes	Perioral muscle dissection	N/R	Minimal discomfort, tension, mild pain, perioral edema, ecchymosis, bleeding and relapse
Bhola et al. (2015) <sup>[10]</sup>	At the mucogingival junction	Twice the amount of the EGD Subclass(E)	The extend of the dynamic smile	Partial thickness	Yes	No	N/R	Minimal morbidity, upper lip tightness
Aly et al. (2016) <sup>[11]</sup>	At the mucogingival junction	6-8 mm superiorly the in the vestibule	maxillary second premolar	Partial thickness	Yes	N/R	Botox injection after 2 weeks from the LRT	After LRT: Slight discomfort, minimal bruising and extraoral swelling. After Botox injection: N/R
Lituma <sup>[12]</sup>	1 mm coronally to the mucogingival line	8-10 mm apical to the mucogingival junction and parallel to the first incision.	Maxillary first molar	partial-thickness	Yes	Grasping the bundle of muscle fibers	Suture containment of the smile elevator muscles	Mild pain, tension and scar formation
Torabi et al. (2018) <sup>[13]</sup>	At the mucogingival junction	In the labial vestibule, at a distance	Maxillary first molar	Partial incision with posterior	Depending on the case	N/R	N/R	Minimal discomfort, scar formation

		based on twice the gingival display		periosteal incisions (Vestibular shallowing)				
Alammar and Heshmeh (2018) <sup>[14]</sup>	1 mm coronal to the mucogingival junction	10 to 12 mm apical and parallel to the lower one	Maxillary first molar	full-thickness	Yes, with a V-shape incision	Dissection of the bony attachments of the perioral muscles	N/R	Scar, tension, minimum of discomfort, ecchymosis, minimal bleeding, moderate edema, pain, flap dehiscence and numbness. Dry Mouth and partial relapse
Tawfik et al. (2018) <sup>[15]</sup>	At the mucogingival line	At twice the distance of the preoperative gingival display	Maxillary first molar	Partial-thickness	Yes	Blunt dissection of the muscle attachment above the coronal incision.	N/R	Slight pain, swelling, scar formation
Vergara-Buenaventura et al. (2016) <sup>[16]</sup>	At the mucogingival junction	At twice the distance of the preoperative gingival display	Maxillary first molar	Partial thickness	No	No	Botox injection the day after LRT	N/R

Zardawi et al. (2020) <sup>[17]</sup>	along mucogingival junction	5 mm coronal to the mucogingival junction	maxillary second premolars	N/R	Yes	dissection of elevator muscles	N/R	N/R
Duruel et al. (2020) <sup>[18]</sup>	At the mucogingival line	At twice the distance of the gingival display during smiling for each tooth region	Maxillary second premolars	Partial-thickness	Yes	Yes, via a periosteal elevation	N/R	N/R
Chacón G. (2020) <sup>[19]</sup>	2 mm apical to the mucogingival line	At the transition line between the masticatory mucosa and the labial line	Maxillary premolars	First a partial-thickness incision. Then, a separate full-thickness is made parallel or at least 5mm apical to the lower horizontal incision	Yes	Blunt dissection of the lip keeping the muscles intact	N/R	Minimal swelling, limited mobility while smiling

N/R:Not reported

<b>Table 2. Combination with adjuvants</b>	
With spacers	<ul style="list-style-type: none"> <li>• Silicone spacers, cartilage, turbinate bone, and Supramid implants<sup>[1]</sup></li> <li>• Polymethylmethacrylate -based bone cement fixed<sup>[2]</sup></li> </ul>
With products	<ul style="list-style-type: none"> <li>• Botox<sup>[3],[4]</sup></li> </ul>
With other surgeries	<ul style="list-style-type: none"> <li>• Combination with gingivectomy alone<sup>[5]</sup>, Gingivectomy and ostectomy<sup>[6-9]</sup></li> </ul>

#### **IV. Versión inicial enviada a publicar**

Type of article: Review Article

Title of the article: **The Lip Repositioning Surgery: A Review of the Technique's Evolution**

Running title : The Lip Repositioning Technique: A Review

Contributors

1. Gonzales-Medina, Kelly, DDS, Department of Periodontology, School of Dentistry, Universidad Científica del Sur, Lima, Peru..

2. Mendoza-Geng, Andrea, DDS, Department of Periodontology, School of Dentistry, Universidad Científica del Sur, Lima, Peru.

3. Vergara-Buenaventura, Andrea, DDS, MSc, PhD(s), Department of Periodontology, School of Dentistry, Universidad Científica del Sur, Lima, Peru.

Department(s) and institution(s)

Department of Periodontology, School of Dentistry, Universidad Científica del Sur, Lima, Peru.

Corresponding Author:

Dr. Andrea Vergara Buenaventura. Universidad Científica del Sur, Calle Cantuarias 398, 15048, Miraflores, Lima, Perú.

Tel. +51994968218

Email: avergarab@cientifica.edu.pe

<https://orcid.org/0000-0002-9395-1010>

Total number of pages: 7

Total number of photographs: 3

Word counts

for abstract: 149

for the text: 3533

Source(s) of support: no

Conflicting Interest (If present, give more details): The authors do not have any financial interest in the companies whose materials are included in this article

## The Lip Repositioning Surgery: A Review of the Technique's Evolution

### Abstract

The lip repositioning technique (LRT) is considered a safe and predictable gummy smile (GS) treatment. However, since Rubinstein and Kostianovsky introduced it in 1973, it has undergone several modifications. This article aims to review and provide a historical compilation of the lip repositioning technique (LRT) evolution to help clinicians understand each technique's description and the rationale for its modifications to treat GS.

An electronic search was performed in Medline, Scopus, and Cochrane Library up to December 2020, including the "lip repositioning" term and studies evaluating or discussing the original LRT's modification in detail. Many LRT modifications have been described in the literature to minimize relapse, morbidity and improve stability involving muscle severance, subperiosteal dissection of the gingiva, frenectomies, and adjunctive product use. Discomfort, scar formation, and pain were the most frequent complications reported. The choice to use a modification should be analyzed and customized to the individual patient's needs.

Keywords: Excessive Gingival Display; Gummy Smile; Lip Repositioning technique; smile



## Introduction

According to some authors, the "ideal smile" involves 1 to 3 mm of exposed gingiva.<sup>[1-3]</sup> Thus, the excessive gingival display (EGD), also called gummy smile (GS), is an aesthetic problem that may affect a person's appearance.<sup>[4-6]</sup> This condition is more frequent in women and during smiling<sup>[7, 8]</sup> and has a prevalence between 11.8%<sup>[9]</sup> and 10.57%.<sup>[10]</sup>

The lip repositioning technique (LRT) described for the first time in plastic surgery by Rubinstein and Kostianovsky<sup>[11]</sup>, is a widely used, effective, safe, and predictable treatment with an average GS reduction of 2.71 mm.<sup>[12, 13]</sup> However, the literature describes several modifications of the original technique using myotomies, subperiosteal dissection of the gingiva, and adjunctive product use.<sup>[14-16]</sup>

Therefore, this article aims to review and provide a historical compilation of the lip repositioning technique (LRT) evolution to help clinicians understand each technique's description and the rationale for its modifications to treat GS.

## Material and methods

### Search strategy

An electronic search in Medline, Scopus, and Cochrane Library databases was performed up to December 2020 to conduct an exploratory narrative review and answer the following questions:

1. What are the different modifications of the original LRT?
2. Which are the basis of the different modifications of the LRT?

The search strategy included the "lip repositioning " term to identify the relevant studies. The search has no language or time restrictions. Additionally, a hand searching of the selected articles was performed.

### Study Selection

Two independent researchers (K.G. and A.M.) performed the search strategy. Titles and abstracts were assessed to identify relevant clinical studies (clinical trials, prospective case series, and case reports). Then, the same calibrated reviewers extracted data from the selected articles into tables. Any disagreement was resolved by consensus with a third examiner (A.V.)

### Diagnose and Case selection

Typically, a patient is diagnosed with GS or EGD when having a high smile line, showing more than 2 mm of free gingiva.<sup>[17]</sup> A thorough examination and correct diagnosis are essential to achieve aesthetic and predictable treatment results.<sup>[18]</sup> It is necessary to emphasize that before any surgical treatment, the gummy smile's etiology must be identified. The GS's etiology is often multifactorial, including altered passive eruption (APE), VME, anterior dentoalveolar extrusion, gingival enlargement, hypermobile upper lip (HUL), short lip, and asymmetrical upper lip.<sup>[2, 8, 19, 20]</sup> When a patient presents gross overbite, vertical maxillary excess (VME), or overgrowth of the upper jaw, orthognathic surgery is the first recommended option.<sup>[4]</sup> However, most patients refuse this surgery due to its high morbidity and the need to be hospitalized.<sup>[21, 22]</sup> The LRT alone could be used when the patient presents short upper lip, HUL (lip mobility >8 mm), and VME except for severe cases<sup>[12, 19, 23]</sup>. Additionally, it may be used in combination with other techniques to treat APE and gingival enlargement<sup>[24, 25]</sup>.

## **The lip repositioning technique**

Rubinstein and Kostianovsky first presented the LRT in 1972 and published it in the plastic surgery field one year later.<sup>[11, 26]</sup> The surgery was based on a strip of maxillary labial mucosa excision to eliminate the lip "over-excursion" while smiling. The gingival display is measured from the gingival margin to the lower border of the upper lip during smiling (Figure 1). This technique performed a turndown flap to close the wound with the lower edge. The distal references of the horizontal incision coincide with the labial commissures' projection during the smile, at the second maxillary molars level. The upper edge of the horizontal incision was placed at the bottom of the upper buccal sulcus, and the lower edge 2 -3 mm above the dentoalveolar line sectioning the frenum. The removal of mucosa was partial, leaving the periosteum intact. (Figure 2). Finally, the lip was immobilized using plaster or adhesive tape. Years later, it was introduced in the dental cosmetic area by Rosenblat and Simon<sup>[27]</sup>.

## **Modifications to the original technique**

### Surgical modifications

The LRT aims to minimize the EGD by reducing the elevator smile muscle's retraction<sup>[28]</sup>. The main modifications related to muscle severance or detachment, frenectomies, and the horizontal incision extension are shown in Table 1.

Litton and Fournier<sup>[4]</sup> reviewed the LRT in 1979. They recommended performing the horizontal incision using the first bicuspid medial side as a reference and a full-thickness flap. Also, suggested muscle detached in cases of short lips. Miskinyar<sup>[5]</sup> performed the original surgery, finding relapses in his patients, and modified the technique by performing an amputation of the levator labii superioris muscle (LLSM). Rosenblat and Simon<sup>[27]</sup> performed the horizontal incision over the mucogingival line from the first molar and sectioning the frenulum. They also

recommended that the amount of tissue removed should be twice the amount of gingival tissue exposed with a maximum of 10-12 mm. On the other hand, a technique to reduce the elevator of the upper lip muscle function was proposed by Ishida et al.<sup>[29]</sup> This procedure required a subperiosteal dissection through a 5-mm columella incision and two 5-mm lateral incisions inside the nostrils. The LLSM was identified and dissected through the lateral incisions. (Figure 3) Besides, the authors performed a frenectomy to lengthen the upper lip.

Jacob and Jacob<sup>[30]</sup> evaluated the LRT with a reversible trial before mucosal cutting using sutures. Then, the incisions and the frenectomy were performed using a high-power diode laser (975 nm, 4 W, CW). In the same year, Ribeiro – Junior et al.<sup>[15]</sup> modified the surgical procedure described by Rosenblat and Simon<sup>[27]</sup> involving two mucosal strip removal, leaving exposed the connective tissue from the midline to the first upper molar and maintaining the frenulum intact. The minor salivary glands were removed when necessary. In the same way, Torabi et al.<sup>[31]</sup> avoided cutting the frenulum and performed periosteal fenestrations. They used extraoral tapes to stabilize tissues as the original LRT.<sup>[26]</sup>

Abdullah et al.<sup>[32]</sup> performed a full-thickness incision 4 to 5 mm above the gingival margins from the second premolar level to the contralateral. A parallel line was made using a surgical caliper at approximately 8 to 10 mm apical to the first incision. After removing the soft tissue strip, the LLSM and depressor septi muscles were released and repositioned in a lower position using circumferential sutures around the canines. In 2015, Bholá et al.<sup>[19]</sup> published a new GS classification and introduced the lip stabilization technique (LipStaT).

Littuma et al.<sup>[33]</sup> described an innovative suture procedure designed to maintain the traction and containment of the smile elevator muscles. After reporting that muscle severance improved EGD reduction, different authors started to perform the technique using a full-thickness flap and the levator muscle myotomy.<sup>[16, 23, 34]</sup> They indicated that this method alters the smile muscles' position, avoiding muscle pull.

Recently, Zardawi et al. <sup>[24]</sup> modified the technique by changing the mucogingival junction position to a more coronal without removing a mucosal strip. On the other hand, Duruel et al. <sup>[35]</sup> presented a tooth-based LRT calculating the amount of mucosa to be removed based on the amount of gum shown for each tooth area. Similarly, Chacon<sup>[36]</sup> performed a calculation of the average tissue to be removed and suggested a microsurgical division of mucosa, periosteum, and bone with periosteum fixation.

It is essential to point out that some authors use a laser to remove the mucosa strip from the maxillary buccal vestibule.<sup>[30, 37-39]</sup>

#### Improvements with the use of adjuvants and spacers

A recent systematic review<sup>[13]</sup> suggested combining the LRT with other approaches such as periodontal plastic surgeries, restorative procedures, or BT injections to obtain more predictable and stable results. A review of the use of adjuvants is shown in Table 2.

Ellenbogen and Swara<sup>[40]</sup> tried to improve the LRT by partial transection of the LLSM by inserting silicone spacers and Supramid implants into a pocket created by an incision inside the nostrils. The use of spacers was intended to fill the muscle space to prevent future reinsertion at the same level. However, the authors reported rejection of Supramid implants. Similarly, it has been suggested to use polymethylmethacrylate (PMMA)-based bone cement fixed to the bone with fixation screws in maxillary overgrowth and subnasal skeletal depression producing a retraction of the upper during smiling. <sup>[41]</sup>

#### Combination with other surgical techniques

On the other hand, some authors recommend combining the LRT with other therapeutic options for GS to ensure more predictable and stable results. One approach is the combination with a gingivectomy.<sup>[15]</sup> However, some authors<sup>[36, 42-44]</sup> recommend using the LRT in association with gingivectomy and osteotomy. In cases of excessive muscle function and HUL, botulinum toxin

type A (BT) has been recommended to prevent muscle contraction<sup>[45]</sup>. Aly et al. suggested it use as an adjuvant two weeks after the lip repositioning surgery<sup>[46]</sup> and other authors the day after.<sup>[47]</sup> BT injections produce lip immobilization during the healing phase, providing long-term stability of the LRT.<sup>[46, 47]</sup>

### **Complications**

Postoperative complications have been described in the literature, being discomfort, scar formation<sup>[15, 23, 27, 30-32, 46]</sup>, and pain<sup>[11, 23, 27, 32]</sup> the most frequently reported.

Other LRT modifications reported swelling,<sup>[34, 46]</sup> ecchymosis,<sup>[27]</sup> edema of the upper lip and perioral area,<sup>[23, 32]</sup> minor bleeding<sup>[23, 32]</sup>, and mucocele formation.<sup>[27]</sup> A review of the complications reported is also shown in Table 1.

### **Conclusion**

Many LRT modifications have been described in the literature and aim to improve the original technique somehow. Several authors support the use of muscle severance to prevent the smile muscle from returning to its original position, while others use adjuvant products to prevent muscle movement during the healing process and minimize potential morbidity. The frenulum section's choice and the extension of the horizontal incision should be customized to the individual patient's needs. The combination with other approaches may ensure more predictable and stable results. Finally, clinicians should know the techniques, advantages, and possible complications to ensure better outcomes.

## REFERENCES

1. Springer NC, Chang C, Fields HW, Beck FM, Firestone AR, Rosenstiel S, et al. Smile esthetics from the layperson's perspective. 2011;139(1):e91-e101.
2. Garber DA, Salama MA. The aesthetic smile: diagnosis and treatment. *Periodontology* 2000. 1996;11:18-28. doi: 10.1111/j.1600-0757.1996.tb00179.x.
3. Kokich VO, Jr., Kiyak HA, Shapiro PA. Comparing the perception of dentists and lay people to altered dental esthetics. *Journal of esthetic dentistry*. 1999;11(6):311-24. doi: 10.1111/j.1708-8240.1999.tb00414.x.
4. Litton C, Fournier P. Simple surgical correction of the gummy smile. *Plastic and reconstructive surgery*. 1979;63(3):372-3. doi: 10.1097/00006534-197903000-00014.
5. Miskinyar SA. A new method for correcting a gummy smile. *Plastic and reconstructive surgery*. 1983;72(3):397-400. doi: 10.1097/00006534-198309000-00027.
6. Guo J, Gong H, Tian W, Tang W, Bai D. Alteration of gingival exposure and its aesthetic effect. *J Craniofac Surg*. 2011;22(3):909-13. doi: 10.1097/SCS.0b013e31820f7f7a.
7. Al-Habahbeh R, Al-Shammout R, Al-Jabrah O, Al-Omari F. The effect of gender on tooth and gingival display in the anterior region at rest and during smiling. *The European journal of esthetic dentistry : official journal of the European Academy of Esthetic Dentistry*. 2009;4(4):382-95.
8. Peck S, Peck L, Kataja M. Some vertical lineaments of lip position. *Am J Orthod Dentofacial Orthop*. 1992;101(6):519-24. doi: 10.1016/0889-5406(92)70126-u.
9. Elhiny OJEJ. Prevalence of gummy smile in a sample of Egyptian population and laymen perception of its attractiveness. 2014;45(June 2014):35-42.
10. Tjan AH, Miller GD, The JG. Some esthetic factors in a smile. *J Prosthet Dent*. 1984;51(1):24-8. doi: 10.1016/s0022-3913(84)80097-9.
11. Kostianovsky AS, Rubinstein AM. The "Unpleasant" smile. *Aesthetic plastic surgery*. 1976;1(1):161-6. doi: 10.1007/bf01570248.
12. Dym H, Pierre R, 2nd. Diagnosis and Treatment Approaches to a "Gummy Smile". *Dental clinics of North America*. 2020;64(2):341-9. doi: 10.1016/j.cden.2019.12.003.
13. Dos Santos-Pereira SA, Cicareli Á J, Idalgo FA, Nunes AG, Kassis EN, Castanha Henriques JF, et al. Effectiveness of lip repositioning surgeries in the treatment of excessive gingival display: A systematic review and meta-analysis. *Journal of esthetic and restorative dentistry : official publication of the American Academy of Esthetic Dentistry [et al]*. 2020. doi: 10.1111/jerd.12695.
14. Silva CO, Ribeiro-Júnior NV, Campos TV, Rodrigues JG, Tatakis DN. Excessive gingival display: treatment by a modified lip repositioning technique. *Journal of clinical periodontology*. 2013;40(3):260-5. doi: 10.1111/jcpe.12046.
15. Ribeiro-Júnior NV, Campos TV, Rodrigues JG, Martins TM, Silva CO. Treatment of excessive gingival display using a modified lip repositioning technique. *The International journal of periodontics & restorative dentistry*. 2013;33(3):309-14. doi: 10.11607/prd.1325.
16. Alammam A, Heshmeh O, Mounajjed R, Goodson M, Hamadah O. A comparison between modified and conventional surgical techniques for surgical lip repositioning in the management of the gummy smile. *Journal of esthetic and restorative dentistry : official publication of the American Academy of Esthetic Dentistry [et al]*. 2018;30(6):523-31. doi: 10.1111/jerd.12433.
17. Monaco A, Streni O, Marci MC, Marzo G, Gatto R, Giannoni M. Gummy smile: clinical parameters useful for diagnosis and therapeutical approach. *The Journal of clinical pediatric dentistry*. 2004;29(1):19-25. doi: 10.17796/jcpd.29.1.y0113r4m06q3k2x0.
18. Silberberg N, Goldstein M, Smidt A. Excessive gingival display--etiology, diagnosis, and treatment modalities. *Quintessence Int*. 2009;40(10):809-18.
19. Bholra M, Fairbairn PJ, Kolhatkar S, Chu SJ, Morris T, de Campos M. LipStaT: The Lip Stabilization Technique- Indications and Guidelines for Case Selection and Classification of



- Excessive Gingival Display. *The International journal of periodontics & restorative dentistry*. 2015;35(4):549-59. doi: 10.11607/prd.2059.
20. Andijani RI, Tatakis DN. Hypermobile upper lip is highly prevalent among patients seeking treatment for gummy smile. *Journal of periodontology*. 2019;90(3):256-62. doi: 10.1002/jper.18-0468.
21. Paik CH, Park HS, Ahn HW. Treatment of vertical maxillary excess without open bite in a skeletal Class II hyperdivergent patient. *The Angle orthodontist*. 2017;87(4):625-33. doi: 10.2319/101816-753.1.
22. Tomaz AFG, Marinho LCN, de Aquino Martins ARL, Lins R, de Vasconcelos Gurgel BC. Impact of orthognathic surgery on the treatment of gummy smile: an integrative review. *Oral and maxillofacial surgery*. 2020;24(3):283-8. doi: 10.1007/s10006-020-00857-4.
23. Alammar AM, Heshmeh OA. Lip repositioning with a myotomy of the elevator muscles for the management of a gummy smile. *Dent Med Probl*. 2018;55(3):241-6. doi: 10.17219/dmp/92317.
24. Zardawi FM, Gul SS, Fatih MT, Hama BJ. Surgical Procedures Reducing Excessive Gingival Display in Gummy Smile Patients With Various Etiologic Backgrounds. *Clinical advances in periodontics*. 2020;10(3):130-4. doi: 10.1002/cap.10089.
25. Gibson MP, Tatakis DN. Treatment of Gummy Smile of Multifactorial Etiology: A Case Report. *Clinical advances in periodontics*. 2017;7(4):167-73. doi: 10.1902/cap.2017.160074.
26. Rubinstein A, Kostianovsky AJPMA. Cirugia estetica de la malformacion de la sonrisa. 1973;60:952.
27. Rosenblatt A, Simon Z. Lip repositioning for reduction of excessive gingival display: a clinical report. *The International journal of periodontics & restorative dentistry*. 2006;26(5):433-7.
28. Simon Z, Rosenblatt A, Dorfman WJTjocd. Eliminating a gummy smile with surgical lip repositioning. 2007;23(1).
29. Ishida LH, Ishida LC, Ishida J, Grynglas J, Alonso N, Ferreira MC. Myotomy of the levator labii superioris muscle and lip repositioning: a combined approach for the correction of gummy smile. *Plastic and reconstructive surgery*. 2010;126(3):1014-9. doi: 10.1097/PRS.0b013e3181e3b6d4.
30. Jacobs PJ, Jacobs BP. Lip repositioning with reversible trial for the management of excessive gingival display: a case series. *The International journal of periodontics & restorative dentistry*. 2013;33(2):169-75. doi: 10.11607/prd.1483.
31. Torabi A, Najafi B, Drew HJ, Cappetta EG. Lip Repositioning with Vestibular Shallowing Technique for Treatment of Excessive Gingival Display with Various Etiologies. *The International journal of periodontics & restorative dentistry*. 2018;38(Suppl):e1-e8. doi: 10.11607/prd.3120.
32. Abdullah WA, Khalil HS, Alhindi MM, Marzook H. Modifying gummy smile: a minimally invasive approach. *J Contemp Dent Pract*. 2014;15(6):821-6. doi: 10.5005/jp-journals-10024-1625.
33. Littuma GJS, de Souza HCM, Peñarrieta GM, Magini RS, Saba-Chujfi E. Lip Repositioning Technique With Smile Elevator Muscle Containment - A Novel Cosmetic Approach for Gummy Smile: Case Report. *Compend Contin Educ Dent*. 2017;38(10):e9-e12.
34. Tawfik OK, Naiem SN, Tawfik LK, Yussif N, Meghil MM, Cutler CW, et al. Lip repositioning with or without myotomy: A randomized clinical trial. *Journal of periodontology*. 2018;89(7):815-23. doi: 10.1002/jper.17-0598.
35. Duruel O, Erduran NE, Tözüm TF. A Modification for Treatment of Excessive Gingival Display: Tooth-Based Lip-Repositioning Technique. *The International journal of periodontics & restorative dentistry*. 2020;40(3):457-61. doi: 10.11607/prd.4465.



36. Chacon G. Modified lip-repositioning technique for the treatment of gummy smile. *The international journal of esthetic dentistry*. 2020;15(4):474-88.
37. Ozturan S, Ay E, Sagir S. Case series of laser-assisted treatment of excessive gingival display: an alternative treatment. *Photomedicine and laser surgery*. 2014;32(9):517-23. doi: 10.1089/pho.2014.3737.
38. Farista S, Yeltiwar R, Kalakonda B, Thakare KS. Laser-assisted lip repositioning surgery: Novel approach to treat gummy smile. *Journal of Indian Society of Periodontology*. 2017;21(2):164-8. doi: 10.4103/jisp.jisp\_411\_16.
39. Suh JJ, Lee J, Park JC, Lim HC. Lip Repositioning Surgery Using an Er,Cr:YSGG Laser: A Case Series. *The International journal of periodontics & restorative dentistry*. 2020;40(3):437-44. doi: 10.11607/prd.4174.
40. Ellenbogen R, Swara N. The improvement of the gummy smile using the implant spacer technique. *Annals of plastic surgery*. 1984;12(1):16-24. doi: 10.1097/00000637-198401000-00004.
41. Arcuri T, da Costa MFP, Ribeiro IM, Barreto BDJ, Lyra eSilva JP. Labial repositioning using polymethylmethacrylate (PMMA)-based cement for esthetic smile rehabilitation-A case report. *International journal of surgery case reports*. 2018;49:194-204. doi: 10.1016/j.ijscr.2018.07.008.
42. Mantovani MB, Souza EC, Marson FC, Corrêa GO, Progiante PS, Silva CO. Use of modified lip repositioning technique associated with esthetic crown lengthening for treatment of excessive gingival display: A case report of multiple etiologies. *Journal of Indian Society of Periodontology*. 2016;20(1):82-7. doi: 10.4103/0972-124x.164746.
43. Sánchez IM, Gaud-Quintana S, Stern JK. Modified Lip Repositioning with Esthetic Crown Lengthening: A Combined Approach to Treating Excessive Gingival Display. *The International journal of periodontics & restorative dentistry*. 2017;37(1):e130-e4. doi: 10.11607/prd.3124.
44. Bhimani RA, Sofia ND. Lip Repositioning, Aesthetic Crown Lengthening, and Gingival Depigmentation: A Combined Approach for a Gummy Smile Makeover. *Journal of cutaneous and aesthetic surgery*. 2019;12(4):240-3. doi: 10.4103/jcas.Jcas\_25\_19.
45. Polo M. Botulinum toxin type A in the treatment of excessive gingival display. *Am J Orthod Dentofacial Orthop*. 2005;127(2):214-8; quiz 61. doi: 10.1016/j.ajodo.2004.09.013.
46. Aly LA, Hammouda NI. Botox as an adjunct to lip repositioning for the management of excessive gingival display in the presence of hypermobility of upper lip and vertical maxillary excess. *Dental research journal*. 2016;13(6):478-83. doi: 10.4103/1735-3327.197039.
47. Vergara-Buenaventura A, Mayta-Tovalino F, Correa A, Breen E, Mendoza-Azpur G. Predictability in Lip Repositioning with Botulinum Toxin for Gummy Smile Treatment: A 3-Year Follow-up Case Series. *The International journal of periodontics & restorative dentistry*. 2020;40(5):703-9. doi: 10.11607/prd.4645.

**Figure Legends**

Figure 1. Illustration of the preoperative gummy smile evaluation.

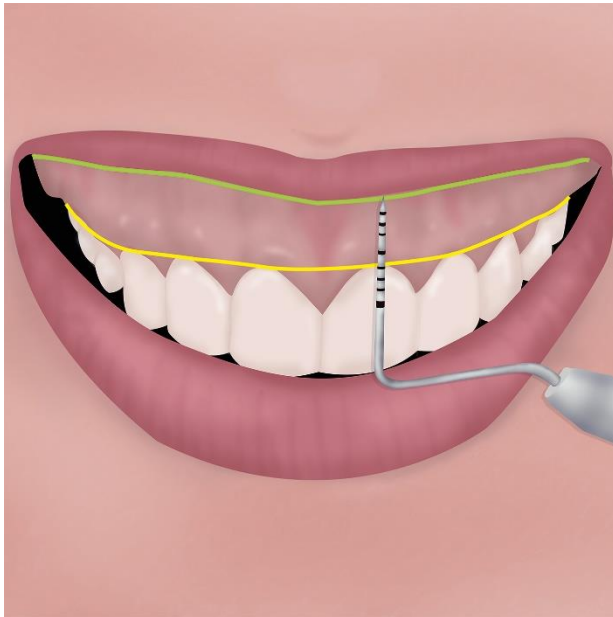


Figure 2. Illustration showing the surgical removal of the mucosal strips.

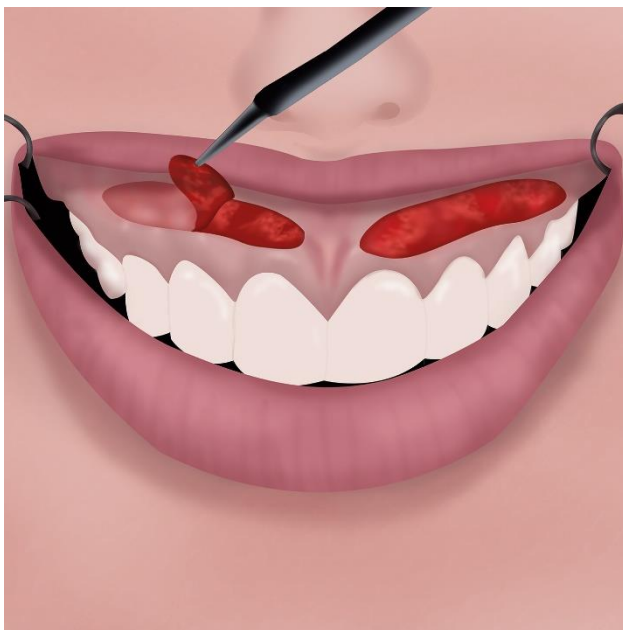
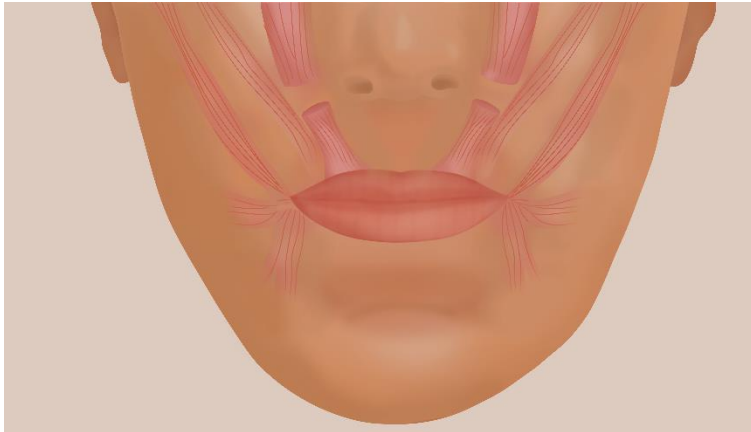


Figure 3. Illustration of the smile muscles showing amputation of both levator labii superioris muscles. Adapted from Ishida et al.<sup>[29]</sup>



**Table 1. Lip repositioning technique and surgical modifications**

<b>Author, (year)</b>	<b>Lower horizontal Incision</b>	<b>Upper horizontal Incision</b>	<b>Distal extension reference</b>	<b>Flap/incision type</b>	<b>Frenulum Section</b>	<b>Muscular modifications</b>	<b>Use of Adjuvants</b>	<b>Complications reported</b>
Rubinstein and Kostianovsky (1973) <sup>[26]</sup>	2 to 3 mm above the dentoalveolar line	At the vestibular sulcus fundus	Projection of the labial commissures.  Second upper molar	Partial-thickness	Yes	N/R	N/R	Mild pain, recurrence
Litton and Fournier, (1979) <sup>[4]</sup> .	In gum, 3-4mm above upper anterior teeth	Along the inner lip mucosa	Medial side of first bicuspid	Full thickness flap	Yes	Muscle detached in cases of short lip	N/R	N/R
Miskinyar, (1983) <sup>[5]</sup>	N/R	Into the sulcus and transversely perpendicular to the bone	N/R	Full thickness flap	N/R	Total or partial Amputation of the levator labii superioris muscle (LLSM).	N/R	Paresthesia

Ellenbogen and Swara, (1984) <sup>[40]</sup>	N/R	From columella to the nostril base	nostril base	Supraperiostally	N/R	the levator labii superioris muscle is partially transected	Silicon, cartilage, turbinate bone and supramid spacers	Supramid implant rejection  Relapse, funny look complaint.
Rosenblatt and Simon, (2006) <sup>[27]</sup>	At the mucogingival junction	10 to 12 mm parallel to the first one, in the labial mucosa	Maxillary first molar	Partial-thickness incision	yes	N/R	N/R	Minimal ecchymosis and tension, slight pain, scar and mucocele formation
Ishida et al., (2010) <sup>[29]</sup>	N/R	5-mm incision in the columella between the caudal septum and alar cartilages	Labial commissures	Full thickness	Yes	Muscular dissection	N/R	uneventful
Ribeiro – Junior et	1 mm coronal to the	10 to 12 mm apical and parallel	Maxillary first molar	Partial-thickness incision	No	No	N/R	Minimal discomfort, minor scar

al. (2013) <sup>[15]</sup>	mucogingival margin	to the first one						
Jacobs and Jacobs (2013) <sup>[30]</sup>	At the mucogingival junction	At a distance based on twice the desired repositioning with a moustache shape, slightly inferior the frenum.	Maxillary first molar	No mucosa removal at the trial, then performed a partial-thickness incision.	Yes	No	Suture placing for reversible trial lip repositioning	Mild discomfort
Abdullah et al. (2014) <sup>[32]</sup>	4 to 5 mm above the gingival margins	Parallel and 8 to 10 mm apical to the first incision	Second Premolar	Full thickness incision	Yes	Perioral muscle dissection	N/R	Minimal discomfort, tension, mild pain, perioral edema, ecchymosis, bleeding and relapse

Bhola et al. (2015) <sup>[19]</sup>	At the mucogingival junction	Twice the amount of the EGD Subclass(E)	The extend of the dynamic smile	Partial thickness	Yes	No	N/R	Minimal morbidity, upper lip tightness
Aly et al. (2016) <sup>[46]</sup>	At the mucogingival junction	6-8 mm superiorly the in the vestibule	maxillary second premolar	Partial thickness	Yes	N/R	Botox injection after 2 weeks from the LRT	After LRT: Slight discomfort, minimal bruising and extraoral swelling.  After Botox injection: N/R
Lituma <sup>[33]</sup>	1 mm coronally to the mucogingival line	8-10 mm apical to the mucogingival junction and parallel to the first incision.	Maxillary first molar	partial-thickness	Yes	Grasping the bundle of muscle fibers	Suture containmen t of the smile elevator muscles	Mild pain, tension and scar formation

Torabi et al. (2018) <sup>[31]</sup>	At the mucogingival junction	In the labial vestibule, at a distance based on twice the gingival display	Maxillary first molar	Partiall incision with posterior periosteal incisions (Vestibular shallowing)	Dependin g on the case	N/R	N/R	Minimal discomfort, scar formation
Alammar and Heshmeh (2018) <sup>[23]</sup>	1 mm coronal to the mucogingival junction	10 to 12 mm apical and parallel to the lower one	Maxillary first molar	full-thickness	Yes, with a V-shape incision	Dissection of the bony attachments of the perioral muscles	N/R	Scar, tension, minimum of discomfort, ecchymosis, minimal bleeding, moderate edema, pain, flap dehiscence and numbness. Dry  Mouth and partial relapse
Tawfik et al. (2018) <sup>[34]</sup>	At the mucogingival line	At twice the distance of the	Maxillary first molar	Partial-thickness	Yes	Blunt dissection of the muscle	N/R	Slight pain, swelling, scar formation



		preoperative gingival display				attachment above the coronal incision.		
Zardawi et al. (2020) <sup>[24]</sup>	along mucogingival junction	5 mm coronal to the mucogingival junction	maxillary second premolars maxillary second premolars	N/R	Yes	dissection of elevator muscles	N/R	N/R
Duruel et al. (2020) <sup>[35]</sup>	At the mucogingival line	At twice the distance of the gingival display during smiling for each tooth region	Maxillary second premolars	Partial-thickness	Yes	Yes, via a periosteal elevation	N/R	N/R
Chacón G. (2020) <sup>[36]</sup>	2 mm apical to the mucogingival line	At the transition line between the masticatory mucosa and	Maxillary premolars	First a partial-thickness incision. Then, a separate full-thickness is made parallel or at least 5mm	Yes	Blunt dissection dissecting the lip keeping the muscles intact	N/R	Minimal swelling, limited mobility while smiling

		the labial line		apical to the lower horizontal incision				
--	--	-----------------	--	---	--	--	--	--

N/R= Not reported

<b>Table 2. Combination with adjuvants</b>	
With spacers	<ul style="list-style-type: none"> <li>• Silicone spacers, cartilage, turbinate bone and Supramid implants<sup>[40]</sup></li> <li>• Polymethylmethacrylate -based bone cement fixed<sup>[41]</sup></li> </ul>
With adjuvant products	<ul style="list-style-type: none"> <li>• Botox<sup>[46],[47]</sup></li> </ul>
With other surgeries	<ul style="list-style-type: none"> <li>• Combination with gingivectomy alone<sup>[15]</sup>, Gingivectomy and ostectomy<sup>[36, 42-44]</sup></li> </ul>

## V. Copias de cartas de respuesta a las observaciones de los revisores

### European Journal of General Dentistry



#### Email

Date/time sent: 2021-05-20 21:46:40
From: Adanir, Nejdethan (necdethan@gmail.com)
To: andreavvb@gmail.com
CC:
BCC: aakanksha.bhatnagar@thieme.in, drzohaibkhusid@gmail.com, necdethan@gmail.com
Attachment:
Title: Revise manuscript (minor revisions)
Text: Manuscript: EJGD-2021-4-3 - (6) - The Lip Repositioning Surgery: A Review of the Technique's Evolution Date submitted: 2021-04-20
Dear Dr. Vergara-Buenaventura
Thank you very much for submitting the above manuscript to the European Journal of General Dentistry.
Your manuscript has now been evaluated by external reviewers and members of the editorial board. Some suggestions were raised and these must be addressed before your manuscript can be accepted for publication.
When you resubmit your manuscript, please provide point-by-point answers to the reviewer's comments in the text field provided during the online resubmission process and highlight any revisions made in your manuscript document.
We look forward to receiving the revised version within three (3) weeks and thank you, again, for submitting your manuscript to the European Journal of General Dentistry.
Sincerely,
Dr. Nejdethan Adanir, DDS, PhD. Editor-in-Chief, European Journal of Dentistry Associate Professor, Department of Restorative Dentistry College of Dentistry, King Faisal University Al Ahsa, KSA, 31982 necdethan@gmail.com
----- Reviewer report: The 'Search strategy' is missing some key information. The number of published articles/ books are not specified. The number of reviewed articles is missing. Critical analysis of existing literature is missing Inclusion/exclusion criteria of the study are missing.

Nejdet Adanir  
Editor-in-Chief  
European Journal of Dentistry

Dear Dr,

We appreciate the encouraging comments, the time and effort that you and the reviewers dedicated to providing feedback on our manuscript “The Lip Repositioning Surgery: A Review of the Technique's Evolution”- EJGD-2021-4-3 - (6) Submitted on: 2021-04-20

**Reviewer comments to be actioned:**

The 'Search strategy' is missing some key information.  
The number of published articles/ books are not specified.  
The number of reviewed articles is missing.  
Critical analysis of existing literature is missing  
Inclusion/exclusion criteria of the study are missing.

Authors' Response:

- We have rewritten the introduction and, we have added the reference [7]
- In the methods: as you suggested, we have added more information about the 'Search strategy', the inclusion/exclusion criteria of the study and a third review question: *Which are the main complications of the LRT modifications?*
- In the results section: we have included the selection results, a flow chart and the number of included/reviewed articles.
- Finally, we have performed a critical analysis of existing literature in the discussion.

We have highlighted in red all the changes we made to the revised manuscript and believe that these changes will improve our manuscript

Thank you in advance for your consideration.  
Best regards,

Dr. Andrea Vergara Buenaventura

**VI. Versión en español (en caso haya sido aceptada en otro idioma):****La cirugía de reposicionamiento de labios: una revisión de la evolución de la técnica****Resumen**

La técnica de reposicionamiento de labios (LRT) se considera un tratamiento seguro y predecible de sonrisa gingival (GS). Sin embargo, desde que Rubinstein y Kostianovsky lo introdujeron en 1973, ha sufrido varias modificaciones. Este artículo tiene como objetivo revisar y proporcionar una recopilación histórica de la evolución de la técnica de reposicionamiento de labios (LRT) para ayudar a los médicos a comprender la descripción de cada técnica y la justificación de sus modificaciones para tratar el GS.

Se realizó una búsqueda electrónica en Medline, Scopus y Cochrane Library hasta diciembre de 2020, que incluyó los términos "reposicionamiento de labios", "técnica de reposicionamiento de labios" o "cirugía de reposicionamiento de labios" y estudios que evalúan o discuten en detalle la modificación del LRT original. La búsqueda no tiene restricciones de idioma ni de tiempo. Además, se realizó una búsqueda manual de las referencias de todos los artículos incluidos.

Las modificaciones descritas en la literatura incluyen rotura muscular, disección subperióstica de la encía, frenectomías y el uso de productos adyuvantes. Su objetivo es minimizar las recaídas, la morbilidad y mejorar la estabilidad. El malestar, la formación de cicatrices y el dolor fueron las complicaciones más frecuentes reportadas. La elección de utilizar una modificación debe analizarse y personalizarse de acuerdo con las necesidades individuales del paciente.

**Keywords:** Excesiva exhibición gingival; Risa contagiosa; Técnica de reposicionamiento de labios; sonrisa

### **Introducción**

Según algunos autores, la "sonrisa ideal" involucra de 1 a 3 mm de encía expuesta. [1-3] Así, la exhibición gingival excesiva (EGD), también llamada sonrisa gingival (GS), es un problema estético que puede afectar a una apariencia de la persona. [4-7] Esta condición es más frecuente en mujeres y durante la sonrisa [8, 9] y tiene una prevalencia entre 11,8% [10] y 10,57%. [11]

Por lo general, a un paciente se le diagnostica GS o EGD cuando tiene una línea de sonrisa alta y muestra más de 2 mm de encía libre. [12] Un examen completo y un diagnóstico correcto son esenciales para lograr resultados de tratamiento estéticos y predecibles. [13] Es necesario destacar que antes de cualquier tratamiento quirúrgico se debe identificar la etiología de la sonrisa gingival. La etiología del GS es a menudo multifactorial, que incluye erupción pasiva alterada (APE), exceso maxilar vertical (VME), extrusión dentoalveolar anterior, agrandamiento gingival, labio superior hipermóvil (HUL), labio corto y labio superior asimétrico. [2, 9, 14, 15] Cuando un paciente presenta sobremordida macroscópica, EMV o sobrecrecimiento de la mandíbula superior, la cirugía ortognática es la primera opción recomendada. [4] Sin embargo, la mayoría de los pacientes rechazan esta cirugía debido a su alta morbilidad y la necesidad de ser hospitalizados. [16, 17]

La técnica de reposicionamiento de labios (LRT) descrita por primera vez en cirugía plástica por Rubinstein y Kostianovsky [18], es un tratamiento ampliamente utilizado, efectivo, seguro y predecible con una reducción de GS promedio de 2,71 mm. [19, 20] La TRL sola podría utilizarse cuando el paciente presenta labio superior corto, HUL

(movilidad del labio > 8 mm) y VME, excepto en casos graves [14, 19, 21]. Sin embargo, la bibliografía describe varias modificaciones del LRT original mediante miotomías, disección subperióstica de la encía y uso de productos complementarios. [22-24]

Por lo tanto, este artículo tiene como objetivo revisar y proporcionar una compilación histórica de la evolución de la técnica de reposicionamiento de labios (LRT) para ayudar a los médicos a comprender la descripción de cada técnica y la justificación de sus modificaciones para tratar el GS.

## **Materiales y métodos**

### **Estrategia de búsqueda**

Se realizó una búsqueda electrónica en Medline (a través de Pubmed), Scopus y Cochrane Library (CENTRAL) hasta diciembre de 2020 para realizar una revisión exhaustiva de la literatura y responder las siguientes preguntas:

1. ¿Cuáles son las diferentes modificaciones del LRT original?
2. ¿Cuáles son la base de las diferentes modificaciones de la LRT?
3. ¿Cuáles son las principales complicaciones de las modificaciones LRT?

La estrategia de búsqueda incluyó los términos "reposicionamiento de labios", "técnica de reposicionamiento de labios" o "cirugía de reposicionamiento de labios" para identificar los estudios relevantes. La búsqueda no tiene restricciones de idioma ni de tiempo. Además, se realizó una búsqueda manual de las referencias de todos los artículos incluidos.

### **Criterios de inclusión / exclusión**

Los ensayos clínicos aleatorizados o no aleatorizados, las series de casos y los informes de casos se consideraron para su inclusión si describían una modificación del LRT original [18]. Se excluyeron los artículos que no proporcionaron detalles adecuados o descripción de la técnica utilizada.

### **La técnica original de reposicionamiento de labios**

Rubinstein y Kostianovsky presentaron por primera vez el LRT en 1972 y lo publicaron en el campo de la cirugía plástica un año después. [18, 25] La cirugía se basó en una tira de escisión de la mucosa labial maxilar para eliminar la "sobreexcursión" del labio mientras sonreía. La visualización gingival se mide desde el margen gingival hasta el borde inferior del labio superior durante la sonrisa (Figura 1). Esta técnica realizó un colgajo de cobertura para cerrar la herida con el borde inferior. Las referencias distales de la incisión horizontal coinciden con la proyección de las comisuras labiales durante la sonrisa, a nivel de los segundos molares superiores. El borde superior de la incisión horizontal se colocó en la parte inferior del surco bucal superior y el borde inferior 2-3 mm por encima de la línea dentoalveolar que secciona el frenillo. La remoción de mucosa fue parcial, dejando intacto el periostio (Figura 2). Finalmente, se inmovilizó el labio con yeso o cinta adhesiva.

### **Selección de estudios y extracción de datos**

Dos investigadores independientes (KG y A.M.) realizaron de forma independiente la estrategia de búsqueda. Los títulos y resúmenes se evaluaron de forma independiente para identificar estudios clínicos relevantes. Se realizó una selección de artículos de texto completo para identificar los artículos que cumplieran con los criterios de inclusión. Luego,



los mismos revisores extrajeron los datos de los artículos seleccionados en tablas. Cualquier desacuerdo se resolvió por consenso con un tercer examinador (A.V.)

Los artículos incluidos fueron evaluados minuciosamente por el contenido relacionado con la técnica de modificación quirúrgica LRT. Los datos extraídos incluyeron: Autor (año), modificaciones en la incisión horizontal inferior y superior, referencias de extensión distal, tipo de colgajo / incisión, información sobre la sección del frenillo, modificaciones musculares, uso de adyuvantes. Además, se resumieron los datos sobre todas las complicaciones posoperatorias.

## **Resultados**

Se seleccionaron un total de 633 citas de tres bases de datos; 335 de Scopus, 241 de Medline a través de Pubmed y 57 de Cochrane. La figura 3 muestra el diagrama de flujo. Después de eliminar los artículos duplicados, quedaron 420 artículos para la selección de títulos y resúmenes. Y después de la evaluación del texto completo, solo quedaron 23 estudios para la extracción de datos. Las principales modificaciones relacionadas con la ruptura o desprendimiento muscular, las frenectomías, la extensión de la incisión horizontal y las complicaciones reportadas se muestran en la tabla 1.

La incisión horizontal inferior a lo largo de la unión mucogingival fue la técnica de elección. Sin embargo, con respecto a la incisión horizontal superior, los autores informan que la realizan en el surco [5], la mucosa labial [4, 26]. Por el contrario, otros realizan una proyección apical a la incisión inferior a 5 mm [27], 6 a 8 mm [28], 8 mm [29], 8 a 10 mm [29, 30], entre 10 y 12 mm [23, 24] o dos veces la cantidad de EGD [31-35]. La referencia más frecuente para la proyección distal de la incisión horizontal fue el primer molar superior [21, 23, 30, 32, 35, 36]. Seis autores realizaron una incisión de espesor total [4, 5, 21, 26, 29, 37] y 13 informaron seccionar el frenillo labial.

Con respecto a la ruptura del músculo (Figura 4), los autores recomendaron el desprendimiento del músculo en casos de labios cortos [4], la amputación del músculo [5, 21, 24, 33, 37] y la contención del músculo con suturas [30]. los autores recomiendan combinar LRT con otras opciones terapéuticas para asegurar resultados más predecibles y estables. Los adyuvantes más utilizados fueron la toxina botulínica (BT), [28, 35] y los espaciadores [38, 39]. La TRL con gingivectomía y osteotomía [26, 40-43] fue la cirugía asociada más frecuente. La Tabla 2 muestra el resumen de los adyuvantes usados en combinación con la LRT.

En todos los estudios, la complicación postoperatoria más frecuente fue el malestar, la formación de cicatrices [21, 23, 28, 29, 31, 32, 36] y el dolor [18, 21, 29, 36]. Otras modificaciones de LRT informaron hinchazón, [28, 33] equimosis, [36] edema del labio superior y área perioral, [21, 29] hemorragia leve [21, 29] y formación de mucocele. [36]

## **Discusión**

Entre los procedimientos utilizados para mejorar la GS, el LRT reduce la retracción del músculo elevador de la sonrisa al acortar el vestíbulo, reduciendo la EGD al sonreír [44]. Fue presentado por primera vez en 1972, publicado en el campo de la cirugía plástica por Rubinstein y Kostianovsky [18, 25], e introducido años más tarde en el área de la cosmética dental por Rosenblat y Simon [36]. Este procedimiento ha sido sugerido para pacientes que solicitan un procedimiento menos invasivo en comparación con la cirugía ortognática [16, 17] y ha evolucionado significativamente a lo largo de los años.

Litton y Fournier [4] fueron los primeros en revisarlo en 1979, recomendando una incisión horizontal utilizando el primer lado medial premolar como referencia y un colgajo de espesor completo. Además, sugirió desprendimiento de músculo en casos de labios cortos. Miskinyar [5] realizó la técnica original, encontrando recaídas en sus

pacientes, y la modificó realizando una amputación del músculo elevador del labio superior (LLSM). Después de informar que la ruptura muscular mejoró la reducción de EGD, diferentes autores comenzaron a realizar la técnica utilizando un colgajo de espesor total y la miotomía del músculo elevador. [21, 24, 33] Indicaron que este método altera la posición de los músculos de la sonrisa, evitando el tirón muscular.

Ishida y otros [37] propuso una técnica para reducir la función del músculo elevador del labio superior y una frenectomía para alargar el labio superior. Sin embargo, requirió una disección subperióstica a través de la columela e incisiones laterales dentro de las fosas nasales. Abdullah y otros [29] realizó una incisión de espesor total de 4 a 5 mm por encima de los márgenes gingivales desde el nivel del segundo premolar hasta el contralateral y una línea paralela utilizando un calibre quirúrgico a aproximadamente 8 a 10 mm apical de la primera incisión. Después de retirar la tira de tejido blando, los músculos LLSM y depresor septi se soltaron y se reposicionaron en una posición más baja utilizando suturas circunferenciales alrededor de los caninos. Los autores que apoyan esta modificación mediante la miotomía del LLM informaron menos recurrencias y una mayor estabilidad postoperatoria que la técnica convencional [24]. Aunque la miotomía mostró una tendencia a una mayor reducción de la EGD a los 6 meses de seguimiento, no hay datos a más largo plazo [20].

La complicación postoperatoria más frecuente fue el malestar, la formación de cicatrices [21, 23, 28, 29, 31, 32, 36] y el dolor [18, 21, 29, 36]. Otras modificaciones de LRT informaron hinchazón, [28, 33] equimosis, [36] edema del labio superior y área perioral, [21, 29] hemorragia leve [21, 29] y formación de mucocele. [36]

Rosenblat y Simon [36] realizaron la incisión horizontal sobre la línea mucogingival desde el primer molar seccionando el frenillo. También recomendaron que la cantidad de tejido extraído sea el doble de la cantidad de tejido gingival expuesto con un máximo de

10-12 mm. Jacob y Jacob [31] evaluaron el LRT con una prueba reversible antes del corte de la mucosa con suturas. A continuación, se realizaron las incisiones y la frenectomía con un láser de diodo de alta potencia (975 nm, 4 W, CW).

Por otro lado, algunas modificaciones incluyeron dejar intacto el frenillo labial maxilar. Ribeiro - Junior y otros [23] modificó el procedimiento quirúrgico descrito por Rosenblat y Simon [36] que implica la extracción de dos tiras mucosas, dejando expuesto el tejido conectivo desde la línea media hasta el primer molar superior y manteniendo intacto el frenillo. De la misma forma, Torabi et al. [32] evitó cortar el frenillo y realizó fenestraciones periósticas. Utilizaron cintas extraorales para estabilizar los tejidos como el LRT original. [25] Del mismo modo, Bholá et al. [14] publicó una nueva clasificación GS e introdujo la técnica de estabilización de labios (LipStaT), evitando seccionar el frenillo.

Las modificaciones recientes tenían como objetivo cambiar la posición de la unión mucogingival a una más coronal sin quitar una tira mucosa [27]. Alternativamente, algunos autores realizan un cálculo personalizado basado en la cantidad de encía mostrada para cada área del diente [34] y sonrisa y exposición papilar. [26]

Se ha sugerido combinar la LRT con otros enfoques como las cirugías plásticas periodontales, los procedimientos de restauración o las inyecciones de BT para obtener resultados más predecibles y estables [20]. En la Tabla 3 se muestra una revisión del uso de adyuvantes. Ellenbogen y Swara [38] intentaron mejorar el LRT mediante una sección parcial del LLSM insertando espaciadores de silicona e implantes Supramid en un bolsillo creado por una incisión dentro de las fosas nasales. Los espaciadores estaban destinados a llenar el espacio muscular para evitar una futura reinserción al mismo nivel. Sin embargo, los autores informaron sobre el rechazo de los implantes Supramid. Asimismo, se ha sugerido utilizar cemento óseo a base de polimetilmetacrilato (PMMA) fijado al

hueso con tornillos de fijación en sobrecrecimiento maxilar y depresión esquelética subnasal, produciendo una retracción del empeine durante la sonrisa. [39]

Por otro lado, algunos autores recomiendan utilizar la LRT con otras opciones terapéuticas en casos de APE, agrandamiento gingival y prevención de recaídas [20, 27, 45]. Un enfoque es la gingivectomía, [23] en asociación con la gingivectomía y la osteotomía [26, 40-42] e incluso con flujos de trabajo digitales [46].

Se ha recomendado la BT tipo A en casos de función muscular excesiva y HUL para prevenir la contracción muscular. [47] Aly y col. sugirieron usarlo como adyuvante dos semanas después de la cirugía de reposicionamiento del labio [28] y otros autores al día siguiente. [35] Las inyecciones de BT producen inmovilización de los labios durante la fase de cicatrización, lo que proporciona estabilidad a largo plazo de la LRT. [28, 35]

### **Conclusión**

Muchas modificaciones de LRT se han descrito en la literatura y tienen como objetivo mejorar la técnica original de alguna manera. Para optimizar la selección de técnicas, es necesario un enfoque individualizado. Varios autores apoyan el uso de la separación muscular para evitar que el músculo de la sonrisa vuelva a su posición original. Por el contrario, otros usan productos adyuvantes para prevenir el movimiento muscular durante el proceso de curación y minimizar la morbilidad potencial. La elección de la sección del frenillo y la extensión de la incisión horizontal deben adaptarse a las necesidades individuales del paciente. La combinación con otros enfoques puede garantizar resultados más predecibles y estables. Finalmente, los médicos deben conocer las técnicas, ventajas y posibles complicaciones para asegurar mejores resultados.

## REFERENCES

- [1] Springer NC, Chang C, Fields HW, Beck FM, Firestone AR, Rosenstiel S, et al. Smile esthetics from the layperson's perspective. 2011;139:e91-e101.
- [2] Garber DA, Salama MA. The aesthetic smile: diagnosis and treatment. *Periodontology* 2000. 1996;11:18-28. doi: 10.1111/j.1600-0757.1996.tb00179.x.
- [3] Kokich VO, Jr., Kiyak HA, Shapiro PA. Comparing the perception of dentists and lay people to altered dental esthetics. *Journal of esthetic dentistry*. 1999;11:311-24. doi: 10.1111/j.1708-8240.1999.tb00414.x.
- [4] Litton C, Fournier P. Simple surgical correction of the gummy smile. *Plastic and reconstructive surgery*. 1979;63:372-3. doi: 10.1097/00006534-197903000-00014.
- [5] Miskinyar SA. A new method for correcting a gummy smile. *Plastic and reconstructive surgery*. 1983;72:397-400. doi: 10.1097/00006534-198309000-00027.
- [6] Guo J, Gong H, Tian W, Tang W, Bai D. Alteration of gingival exposure and its aesthetic effect. *J Craniofac Surg*. 2011;22:909-13. doi: 10.1097/SCS.0b013e31820f7f7a.
- [7] Ayyildiz E, Tan E, Keklik H, Demirtag Z, Celebi AA, Pithon MM. Esthetic impact of gingival plastic surgery from the dentistry students' perspective. *European journal of dentistry*. 2016;10:397-402. doi: 10.4103/1305-7456.184164.
- [8] Al-Habahbeh R, Al-Shammout R, Al-Jabrah O, Al-Omari F. The effect of gender on tooth and gingival display in the anterior region at rest and during smiling. *The European journal of esthetic dentistry : official journal of the European Academy of Esthetic Dentistry*. 2009;4:382-95.
- [9] Peck S, Peck L, Kataja M. Some vertical lineaments of lip position. *Am J Orthod Dentofacial Orthop*. 1992;101:519-24. doi: 10.1016/0889-5406(92)70126-u.
- [10] Elhiny OJEOJ. Prevalence of gummy smile in a sample of Egyptian population and laymen perception of its attractiveness. 2014;45:35-42.

- [11] Tjan AH, Miller GD, The JG. Some esthetic factors in a smile. *J Prosthet Dent.* 1984;51:24-8. doi: 10.1016/s0022-3913(84)80097-9.
- [12] Monaco A, Streni O, Marci MC, Marzo G, Gatto R, Giannoni M. Gummy smile: clinical parameters useful for diagnosis and therapeutical approach. *The Journal of clinical pediatric dentistry.* 2004;29:19-25. doi: 10.17796/jcpd.29.1.y0113r4m06q3k2x0.
- [13] Silberberg N, Goldstein M, Smidt A. Excessive gingival display--etiology, diagnosis, and treatment modalities. *Quintessence Int.* 2009;40:809-18.
- [14] Bhola M, Fairbairn PJ, Kolhatkar S, Chu SJ, Morris T, de Campos M. LipStaT: The Lip Stabilization Technique- Indications and Guidelines for Case Selection and Classification of Excessive Gingival Display. *The International journal of periodontics & restorative dentistry.* 2015;35:549-59. doi: 10.11607/prd.2059.
- [15] Andijani RI, Tatakis DN. Hypermobility upper lip is highly prevalent among patients seeking treatment for gummy smile. *Journal of periodontology.* 2019;90:256-62. doi: 10.1002/jper.18-0468.
- [16] Paik CH, Park HS, Ahn HW. Treatment of vertical maxillary excess without open bite in a skeletal Class II hyperdivergent patient. *The Angle orthodontist.* 2017;87:625-33. doi: 10.2319/101816-753.1.
- [17] Tomaz AFG, Marinho LCN, de Aquino Martins ARL, Lins R, de Vasconcelos Gurgel BC. Impact of orthognathic surgery on the treatment of gummy smile: an integrative review. *Oral and maxillofacial surgery.* 2020;24:283-8. doi: 10.1007/s10006-020-00857-4.
- [18] Kostianovsky AS, Rubinstein AM. The "Unpleasant" smile. *Aesthetic Plast Surg.* 1976;1:161-6. doi: 10.1007/bf01570248.
- [19] Dym H, Pierre R, 2nd. Diagnosis and Treatment Approaches to a "Gummy Smile". *Dental clinics of North America.* 2020;64:341-9. doi: 10.1016/j.cden.2019.12.003.

- [20] Dos Santos-Pereira SA, Cicareli Á J, Idalgo FA, Nunes AG, Kassis EN, Castanha Henriques JF, et al. Effectiveness of lip repositioning surgeries in the treatment of excessive gingival display: A systematic review and meta-analysis. *Journal of esthetic and restorative dentistry : official publication of the American Academy of Esthetic Dentistry* [et al]. 2020. doi: 10.1111/jerd.12695.
- [21] Alammar AM, Heshmeh OA. Lip repositioning with a myotomy of the elevator muscles for the management of a gummy smile. *Dent Med Probl.* 2018;55:241-6. doi: 10.17219/dmp/92317.
- [22] Silva CO, Ribeiro-Júnior NV, Campos TV, Rodrigues JG, Tatakis DN. Excessive gingival display: treatment by a modified lip repositioning technique. *Journal of clinical periodontology.* 2013;40:260-5. doi: 10.1111/jcpe.12046.
- [23] Ribeiro-Júnior NV, Campos TV, Rodrigues JG, Martins TM, Silva CO. Treatment of excessive gingival display using a modified lip repositioning technique. *Int J Periodontics Restorative Dent.* 2013;33:309-14. doi: 10.11607/prd.1325.
- [24] Alammar A, Heshmeh O, Mounajjed R, Goodson M, Hamadah O. A comparison between modified and conventional surgical techniques for surgical lip repositioning in the management of the gummy smile. *Journal of esthetic and restorative dentistry : official publication of the American Academy of Esthetic Dentistry* [et al]. 2018;30:523-31. doi: 10.1111/jerd.12433.
- [25] Rubinstein A, Kostianovsky AJPMA. Cirugia estetica de la malformacion de la sonrisa. 1973;60:952.
- [26] Chacon G. Modified lip-repositioning technique for the treatment of gummy smile. *The international journal of esthetic dentistry.* 2020;15:474-88.



- [27] Zardawi FM, Gul SS, Fatih MT, Hama BJ. Surgical Procedures Reducing Excessive Gingival Display in Gummy Smile Patients With Various Etiologic Backgrounds. *Clinical advances in periodontics*. 2020;10:130-4. doi: 10.1002/cap.10089.
- [28] Aly LA, Hammouda NI. Botox as an adjunct to lip repositioning for the management of excessive gingival display in the presence of hypermobility of upper lip and vertical maxillary excess. *Dental research journal*. 2016;13:478-83. doi: 10.4103/1735-3327.197039.
- [29] Abdullah WA, Khalil HS, Alhindi MM, Marzook H. Modifying gummy smile: a minimally invasive approach. *J Contemp Dent Pract*. 2014;15:821-6. doi: 10.5005/jp-journals-10024-1625.
- [30] Littuma GJS, de Souza HCM, Peñarrieta GM, Magini RS, Saba-Chujfi E. Lip Repositioning Technique With Smile Elevator Muscle Containment - A Novel Cosmetic Approach for Gummy Smile: Case Report. *Compend Contin Educ Dent*. 2017;38:e9-e12.
- [31] Jacobs PJ, Jacobs BP. Lip repositioning with reversible trial for the management of excessive gingival display: a case series. *The International journal of periodontics & restorative dentistry*. 2013;33:169-75. doi: 10.11607/prd.1483.
- [32] Torabi A, Najafi B, Drew HJ, Cappetta EG. Lip Repositioning with Vestibular Shallowing Technique for Treatment of Excessive Gingival Display with Various Etiologies. *The International journal of periodontics & restorative dentistry*. 2018;38:e1–e8. doi: 10.11607/prd.3120.
- [33] Tawfik OK, Naiem SN, Tawfik LK, Yussif N, Meghil MM, Cutler CW, et al. Lip repositioning with or without myotomy: A randomized clinical trial. *Journal of periodontology*. 2018;89:815-23. doi: 10.1002/jper.17-0598.

- [34] Duruel O, Erduran NE, Tözüm TF. A Modification for Treatment of Excessive Gingival Display: Tooth-Based Lip-Repositioning Technique. *Int J Periodontics Restorative Dent*. 2020;40:457-61. doi: 10.11607/prd.4465.
- [35] Vergara-Buenaventura A, Mayta-Tovalino F, Correa A, Breen E, Mendoza-Azpur G. Predictability in Lip Repositioning with Botulinum Toxin for Gummy Smile Treatment: A 3-Year Follow-up Case Series. *The International journal of periodontics & restorative dentistry*. 2020;40:703-9. doi: 10.11607/prd.4645.
- [36] Rosenblatt A, Simon Z. Lip repositioning for reduction of excessive gingival display: a clinical report. *The International journal of periodontics & restorative dentistry*. 2006;26:433-7.
- [37] Ishida LH, Ishida LC, Ishida J, Grynglas J, Alonso N, Ferreira MC. Myotomy of the levator labii superioris muscle and lip repositioning: a combined approach for the correction of gummy smile. *Plast Reconstr Surg*. 2010;126:1014-9. doi: 10.1097/PRS.0b013e3181e3b6d4.
- [38] Ellenbogen R, Swara N. The improvement of the gummy smile using the implant spacer technique. *Annals of plastic surgery*. 1984;12:16-24. doi: 10.1097/00000637-198401000-00004.
- [39] Arcuri T, da Costa MFP, Ribeiro IM, Barreto BDJ, Lyra eSilva JP. Labial repositioning using polymethylmethacrylate (PMMA)-based cement for esthetic smile rehabilitation-A case report. *International journal of surgery case reports*. 2018;49:194-204. doi: 10.1016/j.ijscr.2018.07.008.
- [40] Mantovani MB, Souza EC, Marson FC, Corrêa GO, Progiante PS, Silva CO. Use of modified lip repositioning technique associated with esthetic crown lengthening for treatment of excessive gingival display: A case report of multiple etiologies. *Journal of Indian Society of Periodontology*. 2016;20:82-7. doi: 10.4103/0972-124x.164746.

- [41] Sánchez IM, Gaud-Quintana S, Stern JK. Modified Lip Repositioning with Esthetic Crown Lengthening: A Combined Approach to Treating Excessive Gingival Display. *The International journal of periodontics & restorative dentistry*. 2017;37:e130-e4. doi: 10.11607/prd.3124.
- [42] Bhimani RA, Sofia ND. Lip Repositioning, Aesthetic Crown Lengthening, and Gingival Depigmentation: A Combined Approach for a Gummy Smile Makeover. *Journal of cutaneous and aesthetic surgery*. 2019;12:240-3. doi: 10.4103/jcas.Jcas\_25\_19.
- [43] Boeira PO, De Rossi A, Caporossi LS, Lima GDS. Periodontal esthetic surgery to improve a natural smile: Report case with 2-year follow-up. *Journal of Indian Society of Periodontology*. 2020;24:87-91. doi: 10.4103/jisp.jisp\_477\_18.
- [44] Simon Z, Rosenblatt A, Dorfman WJ. Eliminating a gummy smile with surgical lip repositioning. 2007;23.
- [45] Gibson MP, Tatakis DN. Treatment of Gummy Smile of Multifactorial Etiology: A Case Report. *Clinical advances in periodontics*. 2017;7:167-73. doi: 10.1902/cap.2017.160074.
- [46] Ahmed WM, Hans A, Verhaeghe TV, Nguyen C. Managing Excessive Gingival Display Using a Digital Workflow. *Journal of prosthodontics : official journal of the American College of Prosthodontists*. 2020;29:443-7. doi: 10.1111/jopr.13181.
- [47] Polo M. Botulinum toxin type A in the treatment of excessive gingival display. *Am J Orthod Dentofacial Orthop*. 2005;127:214-8; quiz 61. doi: 10.1016/j.ajodo.2004.09.013.

**Anexos**

Figura 1. Ilustración de la evaluación preoperatoria de la sonrisa gingival.

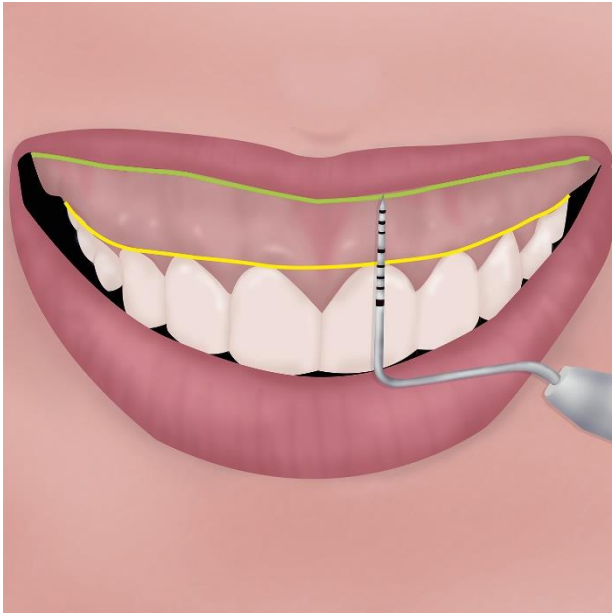


Figura 2. Ilustración que muestra la extirpación quirúrgica de las tiras mucosas.

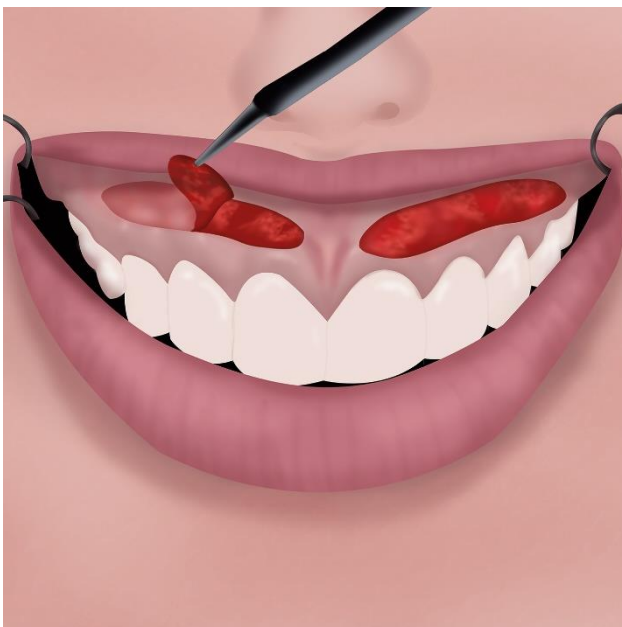


Figura 3 Diagrama de flujo de la selección del estudio

Fig 3. Prisma Flow chart

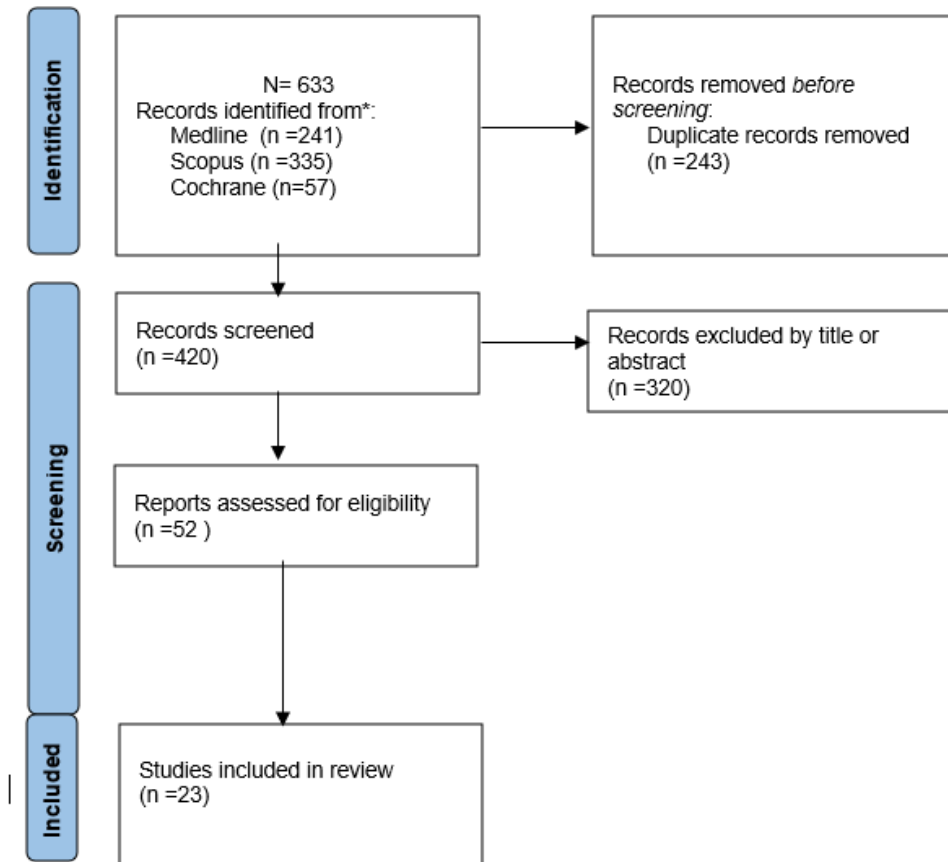
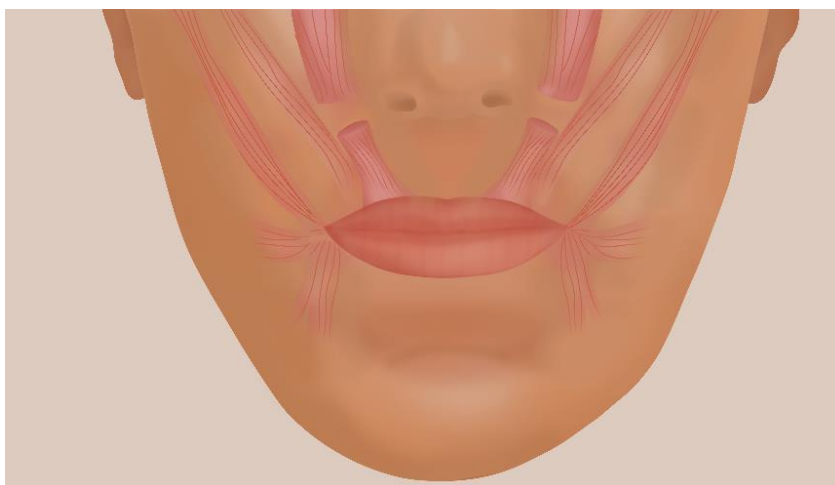


Figura 4. Ilustración de los músculos de la sonrisa que muestra la amputación de ambos músculos elevadores del labio superior. Adaptado de Ishida et al. [37]



## VII. Abreviaturas

1. **LRT**: Lip repositioning technique (Técnica de reposicionamiento labial).
2. **GS**: Gingival smile (Sonrisa gingival).
3. **EGD**: Excessive gingival display (Exhibición gingival excesiva).
4. **APE**: Altered passive eruption (Erupción pasiva alterada).
5. **VME**: Vertical maxillary excess (Exceso maxilar vertical).
6. **HUL**: Hypermobile upper lip (Labio superior hipermóvil).
7. **LLSM**: Levator labii superioris muscle (Músculo elevador del labio superior).
8. **LipStaT**: Lip stabilization technique (Técnica de estabilización de labios).
9. **PMMA**: Polymethylmethacrylate (Polimetilmetacrilato).
10. **BT**: Botulinum toxin (Tóxina botulínica).

## VIII. Anexos:

### 1. Prueba de imprenta del artículo o carta de aceptación de ser el caso

European Journal of General Dentistry



Title: The Lip Repositioning Surgery: A Review of the Technique's Evolution

#### Decision correspondence

Decision: **Accept**

Date of decision: 2021-06-06

Decision email title: Accept manuscript

Decision email text: Manuscript: EJGD-2021-4-3/R1 RESUBMISSION - (6) - The Lip Repositioning Surgery: A Review of the Technique's Evolution

Date submitted: 2021-06-03

Dear Dr. Vergara-Buenaventura

It is a pleasure to inform you that your manuscript is now acceptable for publication in the European Journal of General Dentistry. Proofs of your manuscript and Copyright Transfer Agreement will be sent by the production team in due course.

Sincerely,

Dr. Nejdeth Adanir, DDS, PhD.  
 Editor-in-Chief, European Journal of Dentistry  
 Associate Professor, Department of Restorative Dentistry  
 College of Dentistry, King Faisal University  
 Al Ahsa, KSA, 31982  
 necdethan@gmail.com

## 2. Copia de carta de aprobación académica

**FORMATO DE DEFENSA DE PROYECTO DE TESIS O REVISIÓN ACADÉMICA  
PARA REVISIÓN DE LITERATURA  
(APLICADO SOLO PARA ESPECIALIDAD Y PARA EL TRABAJO DE INVESTIGACIÓN PARA BACHILLER)**

Lima 30 de marzo del 2021

Nº de Registro: N° 578-2020-POS99

<b>Título:</b> "TÉCNICAS DE REPOSICIONAMIENTO LABIAL PARA LA CORRECCIÓN DE LA SONRISA GINGIVAL: UNA REVISIÓN NARRATIVA"				
<b>Alumno/a:</b> KELLY GONZÁLES MEDINA				
Secciones del Protocolo:	Presenta y está correcto	Presenta y esta incorrecto	No Presenta	Observaciones
1. Carátula.	X			Colocar en letras mayúsculas los nombres del tesista y asesor
2. Pregunta de investigación.	X			
3. Introducción.	X			Añadir más referencias
4. Justificación.	X			Mejorar redacción
5. Objetivos.	X			
6. Temas de revisión.	X			Añadir tema de complicaciones
7. Limitaciones del estudio.	X			
8. Cronograma de trabajo.	X			Añadir envío a revista científica, modificar meses
9. Presupuesto.	X			
10. Referencias bibliográficas.	X			Corregir según formato Vancouver modificado (no colocar en cursiva la revista)
11. Anexos.	X			Añadir imágenes de las técnicas

**Sugerencias:** Revisar signos de puntuación

**Observaciones:**

**Informe concluye:**

a) Aprobado con pase a Comité de Ética	c) Aprobado y Requiere solucionar observaciones	b) Desaprobado
X		



**Presidente**

NOMBRES Y APELLIDOS: ERICK VALDIVIA FRÍAS  
DNL 40137425



**Miembro**

NOMBRES Y APELLIDOS: PEDRO LUIS TINEDO LÓPEZ  
DNL 45159119



### 3. Copia de documento de aprobación de comité de ética

COMITÉ INSTITUCIONAL DE ÉTICA EN  
INVESTIGACIÓN



#### CONSTANCIA N° 217-CIEI-CIENTÍFICA-2021

El presidente del Comité Institucional de Ética en Investigación de la Universidad Científica del Sur (CIEI-CIENTÍFICA) da constancia que el proyecto de investigación, cuyos datos se registran a continuación, ha sido **aprobado** por el CIEI-CIENTÍFICA.

Código de registro: **578-2020-POS99**  
 Título: **Técnica de reposicionamiento labial para la corrección de la sonrisa gingival. Una revisión narrativa**  
 Investigador(a): **Kelly Consuelo Gonzales Medina**

La aprobación del proyecto de investigación implica que el documento presentado a evaluación cumple con los lineamientos de Universidad en materia de investigación y ética, los cuales se sustentan en la normativa internacional vigente. Adicionalmente, en el contexto de la pandemia de enfermedad por COVID-19, le recomendamos cumplir

En tal sentido, esta aprobación carecerá de valor si es que el proyecto de investigación arriba indicado es modificado de cualquier forma. Toda enmienda, añadido, eliminación o eventualidad (eventos adversos, etc.) posterior a la fecha de aprobación debe ser reportado al CIEI-CIENTÍFICA.

La vigencia de la aprobación de este documento es de dieciocho (18) meses (**hasta el 3 de diciembre del 2022**), periodo en el que puede desarrollarse el proyecto. Cualquier trámite para su renovación deberá ser enviado antes del término de la vigencia de este documento, debiendo suspenderse todo desarrollo hasta que la renovación sea aprobada. La presente aprobación será ratificada en la sesión del CIEI más próxima.

Villa El Salvador, 4 de junio de 2021




Mg. Fulton Paul Rivera Albinagorta  
 Presidente  
 Comité Institucional de Ética en Investigación

#### 4. Copia de resolución de aprobación del proyecto de tesis



#### RESOLUCIÓN DIRECTORAL DE ACEPTACIÓN DEL PROYECTO DE TESIS Y NOMBRAMIENTO DEL ASESOR

#### RESOLUCIÓN DIRECTORAL DE LA CARRERA DE ESTOMATOLOGÍA N° 030-DACE-DAFCS-U. CIENTÍFICA-2021

Lima, 28 de junio del 2021

**VISTO:**

El informe técnico del Comité Institucional de Ética en Investigación de la Universidad Científica del Sur con código N° 578-2020-POS99 se aprueba el proyecto de Tesis Titulado: "LA CIRUGÍA DE REPOSICIONAMIENTO LABIAL: UNA REVISIÓN DE LA EVOLUCIÓN DE LA TÉCNICA" presentado por KELLY CONSUELO GONZALES MEDINA.

**CONSIDERANDO:**

Que, de acuerdo al Reglamento General de la Universidad Científica del Sur y los reglamentos de pre/posgrado para obtener el Título de **ESPECIALISTA EN PERIODONCIA E IMPLANTES** en la Carrera de Estomatología de la Universidad Científica del Sur, se debe desarrollar un trabajo de investigación.

Que, de acuerdo con la normativa vigente de la Universidad Científica del Sur, en uso de las atribuciones conferidas al Director Académico de Carrera.

**SE RESUELVE:**

**ART. 1º: APROBAR E INSCRIBIR** el Proyecto de Tesis titulado: "LA CIRUGÍA DE REPOSICIONAMIENTO LABIAL: UNA REVISIÓN DE LA EVOLUCIÓN DE LA TÉCNICA" de la CD. KELLY CONSUELO GONZALES MEDINA, con registro: N° 578-2020-POS99 y establecer el inicio de periodo de ejecución del mencionado proyecto 04 de junio del 2021.

**ART. 2º: NOMBRAR** Asesor/a del trabajo de tesis señalado, a al/la Mg. **Andrea Victoria Vergara Buenaventura**.

Regístrese, comuníquese y archívese.



**Dr. Claudio Peña Soto**  
Director Académico de la Carrera de Estomatología

